

**Case Report:****Isolated Trochlear Fracture Of The Humerus**

¹Shehzad Anwer, ¹Shuja Uddin, ¹Hasnain Khalid, ¹Rizwan Ul Haq, ¹Adeel Hamid, ¹Mubashir Farhan, ¹Zia Uddin, ¹Mian Muhammad Haneef

¹Department of Orthopedics, General Hospital, Lahore.

ABSTRACT

The fracture of the distal part of the humerus usually involves the capitellum and variable part of the trochlea. The deep position of the trochlea within the elbow joint makes it a rare occurrence and protects it from direct damage. A 23-year-old local man named Mumtaz presented with an intra-articular half-moon-shaped fragment that had traveled and forward, leading us to assume a capitellar fracture. That was fixed through the medial approach of distal humerus. Postoperatively, patient had good pain-free range of motion.

Keywords: Fracture, trochlea, humerus

INTRODUCTION

The first description of an isolated trochlear fracture of the humerus was in 1853 by Laugier. Thus, the trochlea fracture is also sometimes acknowledged as Laugier's fracture. The fracture of the distal part of humerus usually involves capitellum and variable part of the trochlea. The deep position of the trochlea within the elbow joint makes it a rare occurrence and protects it from direct damage. These fractures are known to result in elbow post-traumatic arthritis and instability. Therefore, management of these types of fractures requires a systematic approach, obtaining an articular anatomic reduction and providing a painless, stable and mobile elbow joint³.

The Laugier's fracture, also known as an isolated fracture of the trochlea, is uncommon and frequently accompanied by elbow dislocation, ligamentous injuries, capitellar fractures, radial head fractures, and/or olecranon fractures^{2,9}. Regarding its management, there is no agreement, which is based on trans articular distal humeral fractures. Posterior splint immobilization for 3 weeks is recommended if the fracture is undisplaced⁵.

If there are small unamenable osteochondral fragments, excision followed by early elbow movement is the treatment of choice^{2,10}. Displaced fractures should be anatomically reduced to restore articular congruency, using headless Herbert screws or bioabsorbable screws^{2, 11, 12}.

CASE REPORT

A 23-year old local man named Mumtaz presented with trauma to the right elbow sustained due to

fall from a height. Radiographs revealed an isolated trochlear fracture of the humerus.

A lateral radiograph revealed an intra-articular half-moon-shaped fragment that had traveled forward, leading us to assume a capitellar fracture. Anteroposterior radiographs merely revealed an abnormality of his medial joint area (Fig-1).

A computed tomography (CT) scan confirmed an isolated front-line fracture of his trochlea, without the participation of the capitellum (Fig-2).

Open reduction and internal fixation were planned for our patient. The joint was opened through a medial approach, passing between the triceps brachii in the back and brachialis in the front. His ulnar nerve was dissected and protected. Accessing the joint capsule required de-insertion of the humeral part of his pronator teres, without interrupting the medial collateral ligament, which was intact. His trochlea was fractured across the front line, with the persistence of the posterior wall. The fragment had moved up and forward without any compaction or loss of cartilage substance⁵.

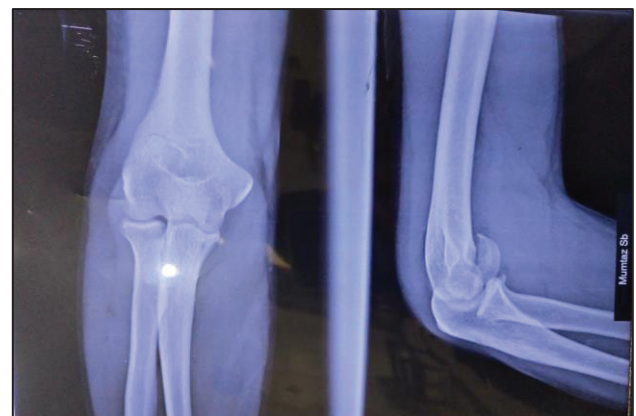

Fig-1: Isolated fracture of trochlea and cranial migration of fragment.

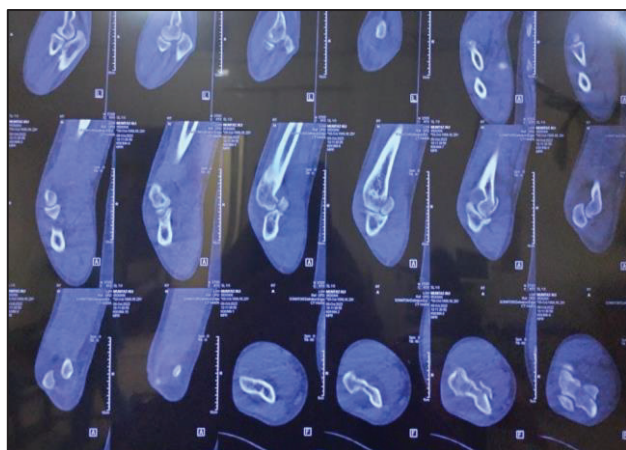


Fig-2: CT scan of elbow localizing the fracture fragment.

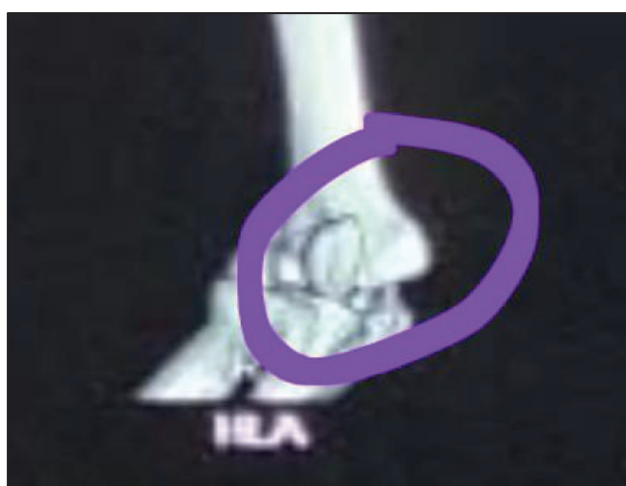

Fig-3: 3D CT scan of elbow showing the isolated trochlea fracture.

An ORIF(Open reduction internal fixation) was done through medial approach and fracture was fixed with Herbert screws. (Fig-4, Fig-5) Post operatively early range of motion exercises of the elbow was commenced. Patient regained nearly full elbow range of movements.

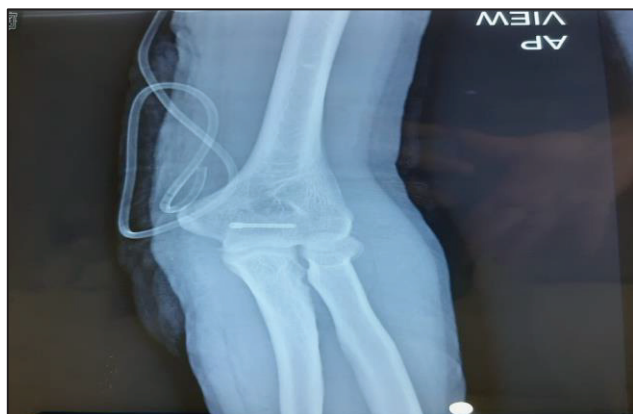

Fig-4: Radiograph AP-view shows fracture fixation via headless screw.

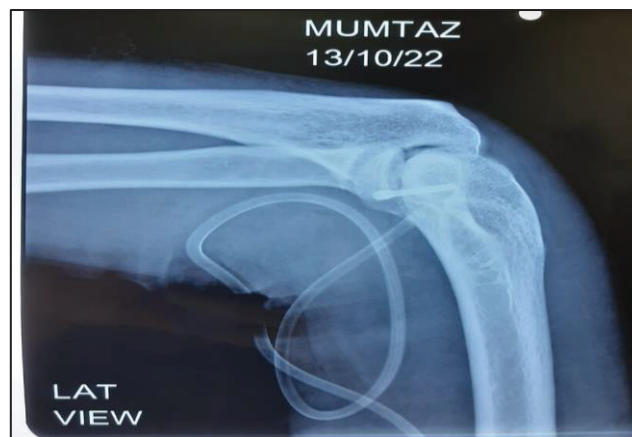

Fig-5: Radiograph Lateral view shows fracture fixation.

This case report describes an isolated fracture of the humeral trochlea treated with open reduction internal fixation. Radiographic union was present at 13 weeks, and at 20 weeks post-op, the patient had regained full elbow range of motion minus 5 degrees of terminal flexion. Open reduction and internal fixation can be performed with success if the trochlear fragment is large enough⁴.

DISCUSSION

The trochlea is an articular surface of the elbow joint and acts as a pulley on which hinged motion of the ulno-humeral joint occurs. Non-operative treatment or excision of coronal shear fractures leads to stiffness or instability of the elbow joint. Fracture of the trochlea is usually associated with elbow dislocation and capitellar or medial condylar fracture⁶. Isolated fracture of the humeral trochlea is very rare. This is explained by its position deep within the trochlear notch cavity and the absence of any muscular or ligamentous attachments at this level, which protects it against direct and indirect trauma⁷.

Isolated trochlear fractures occur as a result of axial loading when the elbow is in extension, such as a fall on an outstretched hand, and the force transmits through the palm and along the ulna.¹³ A role of varus stress with axial loading in isolated trochlear fractures is also suggested¹².

Furthermore, the ulno-humeral joint is subjected to very light compressive and shear forces compared to those experienced by the radio-humeral joint, which explains the high frequency of capitellar fractures compared to trochlear fractures⁸.

Evaluation of radiographs in the anteroposterior view may show an irregularity at the ulno-humeral joint³, but the image can be interpreted 'normal'⁵. In a lateral view, the appearance of an articular

half-moon-shaped fragment moved up and forward could suggest a capitellar fracture. For this reason, diagnosis is based on the results of a CT scan^{3,4}.

It is unclear what caused the trochlear rather than the entire articular capitello-trochlear block to fracture. As the anterior part of the trochlea is subjected to the force from the coronoid process of the ulna in a flexed-elbow position, it selectively causes the coronal shear fracture of the trochlea¹⁴.

The medial approach enables good visualization of the anteromedial aspect of the distal humerus for fixation of trochlear and/or medial epicondylar fractures¹⁵. It avoids the need for the more extensive posterior approach combined with olecranon osteotomy. The lateral approach has limited exposure and cannot fix fractures extending into the capitellum. Therefore, preoperative computed tomography is essential.

In the reported cases, the cancellous screws were passed from the non-articular area. Their direction was oblique, from front to back and from medial to lateral, fixing the trochlea to the capitulum. Alternatively, Herbert screws were inserted into the articular surface buried beneath the cartilage; their direction was perpendicular to the fracture line, securing the fragment of the trochlea to the posterior wall with maximum compression. We opted for this type of osteosynthesis because it is more stable from a biomechanical point of view but the prognosis of coronal trochlear fractures is poor when there is articular cartilage damage (particularly small coronal osteochondral fractures)¹¹.

The trochlear fractures can be fixed using the olecranon osteotomy, which many surgeons may be familiar with. The medial approach enables direct access to the trochlear fracture (particularly anterior coronal fractures), preserves the blood supply, and avoids additional surgical morbidity and complications from olecranon osteotomy. The vascular supply to the trochlea is through its posterior surface. Thus, the posterior approach may disrupt these vessels and increase the risk of avascular necrosis.

In a cadaveric study, trochlear excision leads to considerable instability of the elbow joint¹². Both the capitellum and trochlea have an important role in stability; excision of the trochlea results in multiplanar instability of the ulno-humeral and radio-capitellar joints.

The choice of fixation depends on the size of fragment and the comminution¹⁷. In this case we managed the displaced trochlear fracture using single headless Herbert screw. Herbert and Fischer

in 1984 introduced the double-threaded design of screws that allows them to sink below the articular cartilage level and provide necessary compression for early mobilization^{18,19}. Using the Kirschner wires and compression screws with the combination early range of motion exercise, have also borne successful result.

CONCLUSION

Isolated trochlear fractures are uncommon and only appear infrequently in the literature. We advocate open reduction and internal fixation for displaced fractures where prior studies have indicated that patients had a positive outcome after ORIF. Successful outcomes have been recorded in our case report of solitary trochlear fractures with good ROM and DASH(Disability of arm, shoulder, hand) scores.

REFERENCES

1. Hotchkiss RN, Green DP. Fractures and Dislocations of the Elbow. In: Rockwood CA, Green DP, Bucholz RW, editors. Rockwood and Green's Fractures in Adults. 3rd ed. Philadelphia: Lippincott; 1991. p. 739–841.
2. Dubberley JH, Faber KJ, Macdermid JC, Patterson SD, King GJ. Outcome after open reduction and internal fixation of capitellar and trochlear fractures. *J Bone Joint Surg Am* 2006;88:46–54.
3. Isolated fracture of trochlea: a rare case entity, Dr.GourabBose International Journal of Scientific Research Volume - 9 | Issue - 8 | August – 2020
4. Foulk DA, Robertson PA, Timmerman LA. Fracture of the trochlea. *J Orthop Trauma*. 1995;9(6):530-2. doi: 10.1097/00005131-199509060-00013. PMID: 8592269.
5. Abbassi, N., Abdeljaouad, N., Daoudi, A. *et al*. Isolated fracture of the humeral trochlea: a case report and review of the literature. *J Med Case Reports* 9,121(2015).<https://doi.org/10.1186/s13256-015-0564-1>
6. Grant IR, Miller JH. Osteochondral fracture of the trochlea associated with fracture-dislocation of the elbow. *Injury*. 1975 Feb;6(3):257-60. doi: 10.1016/0020-1383(75)90118-7. PMID: 1126752.
7. Nauth, Aaron MD, FRCSC1; McKee, Michael D. MD, FRCSC1; Ristevski, Bill MD, FRCSC1; Hall, Jeremy MD, FRCSC1; Schemitsch, Emil H. MD, FRCSC1. Distal Humeral Fractures in Adults. *The Journal of Bone & Joint Surgery* 93(7):p 686-700, April 6, 2011. | DOI: 10.2106/JBJS.J.00845
8. Chamseddine A, Hamdan H, Obeid B, Zein H. [Articular coronal fractures of the distal humerus]. *Chirurgie de la Main*. 2009 Dec;28(6):352-362. DOI: 10.1016/j.main.2009.08.009. PMID: 19811942

9. Bryan RS. Fractures about the elbow in adults. *Instr Course Lect* 1981;30:200–23.
10. Ring D, Jupiter JB, Gulotta L. Articular fractures of the distal part of the humerus. *J Bone Joint Surg Am* 2003;85:232–8
11. Ashwood N, Verma M, Hamlet M, Garlapati A, Fogg Q. Transarticular shear fractures of the distal humerus. *J Shoulder Elbow Surg* 2010;19:46–52.
12. Nakatani T, Sawamura S, Imaizumi Y, Sakurai A, Fujioka H, Tomioka M, et al. Isolated fracture of the trochlea: a case report. *J Shoulder Elbow Surg* 2005;14:340–3.
13. Worrell RV. Isolated, displaced fracture of the trochlea. *N Y State J Med* 1971;71:2314–5.
14. Kwan MK, Khoo EH, Chua YP, Mansor A. Isolated displaced fracture of humeral trochlea: a report of two rare cases. *Inj Extra* 2007;28:461–5.
15. Kaushal R, Bhanot A, Gupta PN, Bahadur R. Isolated shear fracture of humeral trochlea. *Inj Extra* 2005;36:210–1.
16. Sabo MT, Fay K, McDonald CP, Ferreira LM, Johnson JA, King GJ. Effect of coronal shear fractures of the distal humerus on elbow kinematics and stability. *J Shoulder Elbow Surg* 2010;19:670–80
17. W. Osman, M. Braiki, Z. Alaya, N. Naouar, M. Ben Ayeche, Combined isolated Laugier’s fracture and distal radial fracture: management and literature review on the mechanism of injury, *Case Rep. Orthop.* 2016 (Figure 2) (2016) 1–6.
18. L.J. Zimmerman, J.J. Jauregui, C.E. Aarons, Isolated shear fracture of the humeral trochlea in an adolescent: a case report and literature review, *J.Pediatr.Orthop.B* 24 (5) (2015) 412–417.
19. A.P. Singh, I.K. Dhammi, A.K. Jain, S. Jain, Neglected isolated fracture of the trochlea humeri, *Chin.J.Traumatol.Engl.Ed.* 13 (4) (2010) 247–249, <https://doi.org/10.3760/cma.j.issn.10081275.2010.04.011>

The Authors:

Dr. Shehzad Anwer,
Consultant Orthopedic Surgeon,
Department of Orthopedic Surgery,
General Hospital, Lahore, Pakistan.

Dr. Shuja Uddin,
Consultant Orthopedic Surgery,
Department of Orthopedic Surgery,
General Hospital, Lahore, Pakistan.

Dr. Hasnain Khalid,
Registrar Orthopedic Surgery,
Department of Orthopedic Surgery,
General Hospital, Lahore, Pakistan.

Dr. Rizwan Ul Haq,
Consultant Orthopedic Surgery,
Department of Orthopedic Surgery,
General Hospital, Lahore, Pakistan.

Dr. Adeel Hamid,
Consultant Orthopedic Surgery,
Department of Orthopedic Surgery,
General Hospital, Lahore, Pakistan.

Mubashir Farhan,
Consultant Orthopedic Surgery,
Department of Orthopedic Surgery,
General Hospital, Lahore, Pakistan.

Dr. Zia Uddin,
Consultant Orthopedic Surgery,
Department of Orthopedic Surgery,
General Hospital, Lahore, Pakistan.

Dr. Mian Muhammad Haneef,
Professor of Orthopedics,
Department of Orthopedic Surgery,
General Hospital, Lahore, Pakistan.

Corresponding Author:

Dr. Shuja Uddin,
Consultant Orthopedic Surgery,
Department of Orthopedic Surgery,
General Hospital, Lahore, Pakistan.
Email: drshujauddin111@gmail.com