



# Pattern of Superficial Veins of Cubital Fossae in Punjabi Students

<sup>1</sup>Fatima Inam,<sup>2</sup>Farah Ishfaq,<sup>3</sup>Muhammad Shahid Akhtar,<sup>4</sup>Faisal Ishfaq,<sup>1</sup>Roomana Hashim

## ABSTRACT

**Introduction:** The superficial veins in the cubital fossae are of significant anatomical and clinical importance. Understanding the variations in these venous patterns is essential for accurately applying diagnostic, surgical, and therapeutic procedures.

**Aims and Objectives:** This study aims to identify superficial venous patterns in the cubital fossae of Punjabi students in Pakistan.

**Place and Duration of Study:** A cross-sectional study was conducted on 180 first- and second-year MBBS students at Akhtar Saeed Medical and Dental College, Lahore, Pakistan, from January to July 2024.

**Materials and Methods:** A cross-sectional study was conducted on 180 first- and second-year MBBS students at Akhtar Saeed Medical and Dental College from January to July 2024, yielding 360 samples from both upper limbs. Participants were randomly selected after obtaining IRB approval and informed consent. Demographic data and domicile were recorded. Data was analyzed using SPSS 22, and chi-square tests were applied to assess associations between venous patterns, body side, gender, and geographical location. A p-value <0.05 was considered statistically significant.

**Results:** Different venous patterns were identified. Pattern 2, an "M" shape, was the most common on both sides left (44.4%) and right (43.3%). A significant difference in venous patterns between the left and right arms of males and females was observed ( $p \leq 0.001$  for both). Males showed a higher frequency of Pattern 2, while females predominantly exhibited Pattern 1. Other patterns accounted for less than 10% of cases, with no significant regional differences.

**Conclusion:** This study identified different patterns in the cubital fossa, with Pattern 2 being the most common and showing significant gender differences. Recognizing these patterns is crucial for improving procedural accuracy and reducing complications in clinical interventions.

**Keywords:** Vascular, Variations, Cephalic, Basilic, Upper extremity

## INTRODUCTION

The venous configuration in the cubital fossa are of significant interest not only from an anatomical standpoint but also due to their clinical relevance. A comprehensive understanding of the various venous patterns in the cubital fossa is essential for diagnosis, surgery, and therapeutic procedures, making the study of their anatomical variations crucial.<sup>1</sup> Superficial veins are located just beneath the skin, within the subcutaneous tissue, and are often visible through the skin, especially in the upper limb.<sup>2</sup>

<sup>1</sup>Akhtar Saeed Medical and Dental College, Lahore. <sup>2</sup>Services Institute of Medical Sciences, Lahore. <sup>3</sup>King Edward Medical University, Lahore. <sup>4</sup>University of Engineering and Technology, Lahore.

### Correspondence:

Dr. Fatima Inam, Associate Professor, Department of Anatomy Akhtar Saeed Medical and Dental College, Lahore.

Email: drfatima74@yahoo.com

Submission Date: 7<sup>th</sup> August 2024

1<sup>st</sup> Revision Date: 8<sup>th</sup> September 2024

Acceptance Date: 9<sup>th</sup> September 2024

These veins are of particular importance as arteries and nerves nearby may be at risk of injury during venipuncture or other procedures if not properly identified.<sup>3</sup> The cephalic and basilic veins originate from the dorsal venous arch of the hand. The cephalic vein ascends along the lateral aspect of the wrist and forearm, crosses the elbow via the median cubital vein, and continues along the anterolateral aspect of the arm. It traverses through the deltoid and pectoralis major muscles within the gap between these two muscles, eventually entering the clavipectoral triangle where it joins the axillary vein after penetrating the costocoracoid membrane.

The basilic vein ascends medially along the forearm and lower arm, where it remains visible through the skin. It transitions into a deeper course near the mid-arm, running in parallel with the brachial artery and medial cutaneous nerve. The basilic vein merges with branches of the axillary vein to contribute to the formation of the axillary vein.<sup>2</sup> The median antebrachial vein originates at the base of the thumb, curving around the wrist and ascending along the front of the forearm. It often joins the median cubital vein to form an "N" shape.<sup>4</sup> At times,

it divides into the median basilic and cephalic veins, resulting in an "M" shape configuration in the cubital region<sup>1</sup>. These anatomical variations have been well documented in standard anatomical textbooks.<sup>1,5,6</sup> Studies conducted on venous patterns in populations from various countries have revealed additional patterns that differ from textbook descriptions, further highlighting the diversity of venous configurations in the cubital fossa<sup>7,8,9</sup>.

These variations underscore the need for region-specific research to better understand local population patterns. So we aim to identify the pattern of superficial veins in cubital fossae in Punjabi students in Pakistan.

## MATERIALS AND METHODS

This is a cross-sectional study, which includes 180 students from First-year and second-year MBBS of Akhtar Saeed Medical and Dental College conducted from January 2024 to July 2024. Students were selected using simple random sampling, after obtaining permission from the IRB ethical review no. (M-19/037/-Anatomy) of the college, resulting in 360 samples from both upper limbs.

The sample size was calculated by entering values into an online tool (Raosoft software) with a 95% confidence interval and a 5% chance of error.<sup>10</sup> The superficial venous patterns in the cubital fossa, was documented by the anatomists, after obtaining written informed consent. Demographic data and domicile were also recorded. Inclusion criteria include all the students who are willing to participate and are from different regions of the province of Punjab. Exclusion criteria include obese subjects, those having any scar in the cubital fossa, and subjects from other provinces were excluded from the study.<sup>11</sup> Participants were divided into three zones of Punjab which included the central zone, the north zone, and the southern zone.<sup>12</sup> The six identified venous patterns are described as follows:

**Pattern 1:** The median cubital vein arises from the cephalic vein a few centimeters below the elbow and merges with the basilic vein a few centimeters above the elbow joint, forming an "N" shape. Additionally, it receives tributaries from the anterior forearm (refer to Figs. 1 and 2).

**Pattern 2:** This configuration features a single median antebrachial vein that splits in the cubital fossa, with one branch joining the basilic vein and the other connecting to the cephalic vein, creating an "M" shape (see Fig. 3).

**Pattern 3:** In this pattern, there is no connection between the cephalic and basilic veins (see Fig. 4).

**Pattern 4:** The cephalic and basilic veins are linked by an arched vein, with the concave side facing proximally. Two or more veins from the anterior forearm drain into this arch.

**Pattern 5:** This arrangement shows merely the presence of the basilic vein, with the absent cephalic vein.

**Pattern 6:** In this pattern, two median cubital veins connect the cephalic and basilic veins. The lower vein corresponds to the typical median cubital vein, while the upper vein forms an arch with its convexity directed proximally.<sup>8</sup>

**Data collection Procedure:** For observing the pattern of superficial veins in the cubital fossae of the subjects, informed written consent was taken and the procedure for observing the pattern was explained to the subjects. To record the observations, both upper limbs were exposed, and the elbow joint was placed in the supine position. The strap was applied 10 cm proximal to the elbow crease for about 3-4 minutes until the veins became prominent for observation<sup>11</sup>. The arrangement of superficial veins in both arms of the subjects were noted. Various patterns on both right and left cubital fossae were observed and Photographs were taken by digital mobile camera. The arrangement of veins in each case was marked in the research tool Performa identified with the age, gender, and domicile of the subject.

**Data analysis and Statistical analysis:** Data was entered into SPSS 22. A descriptive statistical analysis was performed. values were expressed in frequencies, and the chi-square test was employed to assess the association of superficial venous arrangement in the cubital fossa with body side, gender, and geographical location. P-value <0.05 was considered as statistically significant.

## RESULTS

Among the 180 participants, 105 (58.3%) were male, while 75 (41.7%) were female. A total of 360 patterns were observed on both sides. The average age of participants was  $19.64 \pm 4.23$  years, and all participants were from the Punjab province. Pattern 2 was the most common type on both sides, appearing in 80 (44.4%) of left upper limbs and 78 (43.3%) of right upper limbs. Pattern 6 had the lowest frequency, with only 0.6% on the left side and none (0.0%) on the right side. (Table 1).

**Table1: Frequency of each Superficial venous pattern in the right and left arm**

Patterns	Leftarm Total180	Rightarm Total180
1	63(35%)	67(37.2%)
2	80(44.4%)	78(43.3%)
3	33(18.3%)	31(17.22%)
4	2(1.1%)	1(0.6%)
5	2(1.1%)	2(1.1%)
6	0(0%)	1(0.6%)

The p-value of  $\leq 0.001$  in Table No. 2 indicates a statistically significant association between gender and the pattern of veins in the right arm. suggesting that the distribution of vein patterns significantly differs between males and females regarding the right arm.

**Table 2: Frequencies and Chi-square comparison of right arm pattern with gender**

The gender of the participants	Pattern 1 N=67	Pattern 2 N=78	Pattern 3 N=31	P-value
Male	38(56.7%)	51(65.4%)	12(38.7%)	<0.001
Female	29(43.3%)	2(34.6%)	19(61.3%)	

There is a statistically significant association between gender and the patterns observed for the left arm. p-value  $\leq 0.001$ . Males tend to exhibit Pattern 2 more frequently, while females exhibit Pattern 1 commonly. (Table 3)

**Table 3: Frequencies and Chi-square comparison of left arm pattern with gender**

Gender	Pattern1 N=63	Pattern2 N=80	Pattern3 N=33	P-value
Male	36(57.1%)	54(67.5%)	12(36.4%)	<0.001
Female	27(42.9%)	26(32.5%)	21(63.6%)	

The Southern Punjab has the highest number of participants, with a total of 100 individuals. Among the participants from Southern Punjab, 61 are male, constituting 58.1% of the male participants, and 39 are female, making up 52.0% of the female participants. Central Punjab has 59 participants, accounting for 32.8% of the total participants. This region has 30 male participants (28.6%) and 29 females participants (38.7%). North Punjab has the smallest number of participants, with 21 individuals.

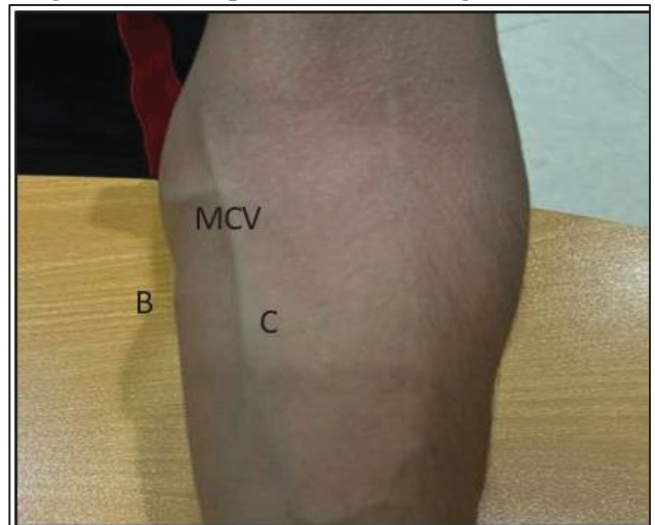
There are 14 males (13.3%) and 7 females (9.3%) from this region (Table 4).

**Table4: Showing geographical distribution of gender Of the participants**

The zones of Punjab	Gender of participants		Total
	male	female	
The Southern Punjab	61 (58.1%)	39 (52.0%)	100 (55.6%)
The Central Punjab	30 (28.6%)	29 (38.7%)	59 (32.8%)
The North Punjab	14 (13.3%)	7 (9.3%)	21 (11.7%)

There is no statistically significant difference in the arrangement of superficial veins in the cubital fossa of the right and left hand among the different zones of Punjab. (P-value  $\leq 0.673$  and  $\leq 0.867$ ) respectively.

**Fig No.1: shows pattern no.1 having N formation**



**Fig.2: Type 1 with N formation showing antibrachial vein draining in the median cubital vein**

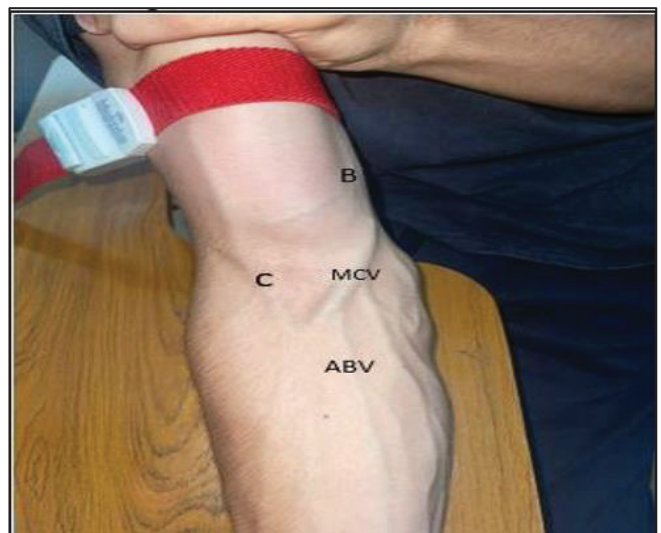




Fig No. 3: showing pattern 2

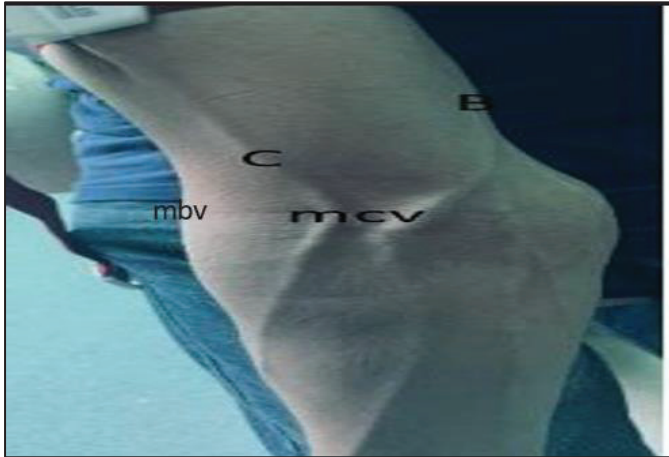
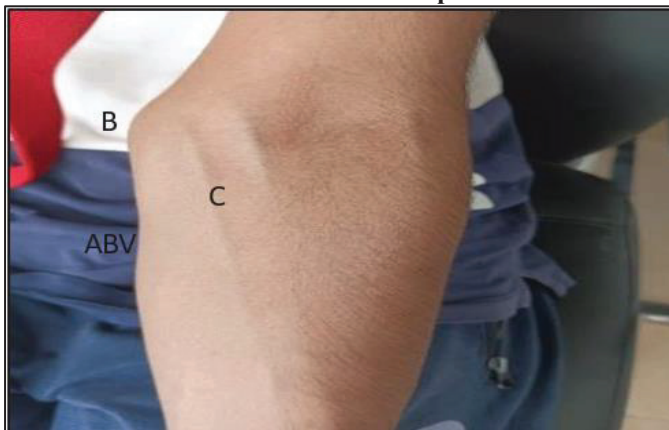

Fig no. 4: Showing pattern 3 shows no communication between basilic and cephalic vein



## DISCUSSION

The study found that the most common venous pattern, pattern 2 (median antebrachial vein branching to both basilic and cephalic creating an M-like pattern) appeared 80 times (44.4%) on the left and 78 times (43.3%) on the right upper limbs. There was a statistically significant association between gender and vein patterns in the right arm, indicating that males were more likely to have Pattern 2, while females more often had Pattern 1. A p-value of 0.673 shows no statistically significant difference in the superficial vein patterns in the right hand's cubital fossa across different Punjab zones. A study conducted on the population of Mithilanchal India, reported type 2 as the most common pattern of superficial veins which was also reported in our study.<sup>8</sup> In another research conducted at Rama University Kanpur India, type 2 pattern was also the most common type observed.<sup>10</sup> However, studies in other populations revealed differing results: in university students from Ardabil, Iran, the N-type pattern was more common, especially in males (70.1%) compared to females (64.7%).<sup>13</sup> Type 1 N pattern of the superficial vein was the most common pattern in both genders and pattern 2 M type was least common in students of Indian University of

Srinagar, Indian Kashmir.<sup>11</sup> In the Nepalese population, the most common type of pattern is the Type 1 N pattern with (33.9%) in males and (43.6%) in females.<sup>7</sup> In this study, there is a statistically significant association between gender and the patterns observed for the left arm.  $p\text{-value} \leq 0.001$ . Males tend to exhibit Patterns 1 and 2 more frequently, while females exhibit Pattern 3 more often. Patterns 4 and 5 have small frequencies, and Pattern 6 is not observed in either gender. In a study conducted on the Pattern of Superficial Veins in the Cubital Fossa of the Nepalese population, the M pattern was found to be predominant in both common type of pattern was N-type and there was no statistically significant difference between the left and right sides.<sup>14</sup> The differences in the frequency of common venous arrangements observed across the studies may be due to racial variations among the populations. However, the study had several limitations, like this study was conducted only in one center so we cannot generalize our findings to entire Punjabi population still this study provides evidence guiding towards prevalent patterns. A larger sample size is necessary to assess patterns in a more diverse population. Our study was unable to detect small vessels and assess their relation with cutaneous nerves in the cubital area. To better visualize vascular patterns, the use of additional tools such as vein finders is recommended. Further cadaveric studies should also be conducted to examine the relationship between these vessels and cutaneous nerves.

## CONCLUSION

Six distinct arrangements of superficial cubital veins were recorded, with the most common being the no.2, an M-shaped pattern formed by the median antebrachial vein branching into the basilic and cephalic veins. This pattern differed from those observed in other populations. Additionally, a significant gender difference was found in the left and right arms in our study. The distribution of vein patterns across three zones in Punjab showed no significant differences on either side. The study concludes that superficial vein patterns in the cubital fossa vary across populations, and understanding these patterns and their prevalence in our region is vital for health care professionals, particularly in emergencies, to ensure safe and effective access.

## REFERENCES

1. Melaku T, Wondmagegn H, Gebremickael A, Tadesse A. Patterns of superficial veins in the cubital fossa and its clinical implications among southern Ethiopian population. *Anatomy & Cell Biology*. 2022 Jun 6;55(2):148.

2. Moore K, Dalley A. Clinically Oriented Anatomy, 9th ed. London: Lippincott and Wilkins: 2023
3. Kishihara Y, Yasuda H, Kashiura M, Moriya T, Shinzato Y, Kotani Y, Kondo N, Sekine K, Shime N, Morikane K, AMOR–VENUS study group. Impact of the failure of initial insertion of a peripheral intravascular catheter on the development of adverse events in patients admitted to the intensive care unit from the emergency room: A post hoc analysis of the AMOR–VENUS study. *Acute Medicine & Surgery*. 2023 Jan;10(1): e850.
4. Mohanty CR, Radhakrishnan RV, Singh N, Ahmad SR, Tharavath V. Venipuncture- associated peripheral nerve injury: Have a Look with POCUS before you leap. *Saudi Journal of Anaesthesia*. 2023 Apr 1;17(2):298-9.
5. Snell RS. *Clinical Anatomy by regions*. 10th edition, edited by Lippincott William & Wilkins. 369. 2018.
6. Standring S. *Gray's Anatomy, International Edition: The Anatomical Basis of Clinical Practice*, 42nd ed. Edinburgh: Elsevier Churchill Livingstone, 2021, 894.
7. Sah SK, Timsinha S, Chaudhary RK, Shah RK, Mehta UK. The pattern of superficial venous arrangement in cubital fossa among preclinical Nepalese MBBS students at Birat Medical College Teaching Hospital. *Asian Journal of Medical Sciences*. 2021 Oct 1;12(10):153.
8. Dhan MR, Suman S, Kumar S, Sinha S K, Singh N. Observation on the anatomical patterns of superficial cubital veins in the population of Mithilanchal. *J Dent Med Sci*. 2019 Nov 27;18(11):30-5.
9. Ouies SM, El-Naeem A, Abeer F. Patterns of Superficial Cubital Veins in Sohag University Students. *The Egyptian Journal of Hospital Medicine*. 2022 Oct 1;89(2):6361-6.
10. Das M, Jahan S, Pankaj P and Kr Sah G. An observational study of the pattern of superficial cubital veins among students of Rama University. *Int J Anat Res*. 2019; 7(3):6835- 6840.
11. Hassan A, Jan S, Jan N, Khan T, Afza R. Anatomical Variations and Vascular Patterns of Superficial Veins in the Cubital Fossa and its Clinical Implications among pre-clinical Medical Students of North India. *Journal of cardiovascular disease research*. 2022;8;13.
12. Tayyub M, Ali S, Javid A, Imran M. Prevalence and diversity of ectoparasites in Wild Rock Pigeon (*Columba livia*) in Punjab region, Pakistan. *Brazilian Journal of Biology*. 2021 Aug 20;83:e246887.
13. Ghasem GM, Nasiri K, Sagha M, Aghamohammadi V, Malekrah A, Eskandari M. Variation of superficial veins of cubital fossa among students of Ardabil University of Medical Sciences. *Translational Research in Anatomy*. 2021 Nov 1; 25:100136.
14. Rana G, Patel AK, Marasini S. Variation of Pattern of Superficial Veins in Cubital Fossa of the Nepalese Blood Donors in Blood Bank of a Tertiary Care Hospital. *JETIR*. 2021, Jan 1;8:667-675

### **The Authors:**

Dr. Fatima Inam  
Associate Professor,  
Department of Anatomy,  
Akhter Saeed Medical and Dental College, Lahore

Dr. Farah Ishfaq  
Student 3rd-year MBBS,  
Services Institute of Medical Sciences, Lahore

Dr. Muhammad Shahid Akhtar  
Associate professor,  
Department of Anatomy,  
King Edward Medical University, Lahore

Faisal Ishfaq  
Student 3<sup>rd</sup> semester BS Computer Science,  
University of Engineering and Technology, Lahore

Dr. Roomana Hashim  
Assistant Professor,  
Department of Anatomy  
Akhter Saeed Medical and Dental College, Lahore

### **Authorship:**

**FI:** Conception, Designing, acquisition & interpretation of data

**FIA:** literature review, data collection

**MSA:** Manuscript drafting, Results evaluation

**FIQ:** Statistical analysis, Reference management

**RH:** Academic & administrative support,  
Data collection