Proceedings S. Z. P. G. M. I. Vol. 2 (1988), pp. 76–83

A Middle Aged Female with Hydatid Disease of Liver

PERVAIZ IQBAL AND KHALID DURRANI
Dept. of General Surgery

HISTORY

G.H. a female of 55, from Behra Surgodha presented in the Medical Out Patient Dept. on 11-4-1987 with pain right leg for the last two months. To begin with, the pain started in the right knee & was more on walking. It gradually increased in intensity and involved the whole limb. There was no history of trauma to right leg or pain in other joints of body.

She was known hypertensive and diabetic for the last one year. She also had a family history of diabetes and hypertension. She was allergic to pencillin.

EXAMINATION

Her general physical examination was unremarkable except that she was very obese had very poor orodental hygiene & her B.P was 160/100 mmHg. Examination of her right leg was also unremarkable but examination of abdomen showed enlarged liver, 5cm below the right costal margin. It was smooth, firm, had regular edge and was non tender. The examination of her chest & cardiovascular system was unrevealing.

INVESTIGATIONS

Her routine investigations were normal except raised blood glucose (220mg/dl) & glycosuria. The chest x-ray was normal. The x-rays lumbar spine showed early degenerative changes in lumbar spine.

The ultrasound abdomen showed enlarged liver, 7.2 cm below right costal margin. Large locular cystic area at the junction of right & left lobe. The appearance was suggestive of hydatid cyst.

Liver scan (Tc 99) : Scan showed enlarged liver image with large area of absent radioactivity near the gall bladder.

Haemagglutination test for Ecchinococus granulosa was requested. It was positive in dilution titer of 1/800.

She was discharged from the hospital for two weeks & advised to report back. She came back after 8 months, this time with occasional pain and discomfort in right hypochondrium, worsening at times. On examination she had enlarged and tender liver, 5cm below right costal margin.

At this stage, surgical consultation was requested, she was advised oral cholecystogram, which was normal and C.T. Scan of abdomen. It showed large locular cystic lesion in right lobe of live & appearance suggested hydatid cyst. (Fig 1)

Fig: 1. Pre-operative CT. Scan Hydatid cyst in Rt. lobe of of liver.

She was shifted to surgical floor. In summary, she was a middle aged diabetic and hypertensive lady, brought up in a village where she had close contact with dogs and sheep. Her brother also suffered from Hydatid cyst of liver & was operated 6 years back. She had heaviness in right hypochondrium for the last few years, discomfort in right hypochondrium for the last 8 mouths. On examination was found to be having enlarged liver. The ultrasound abdomen showed hydatid cyst. It was confimed by C.T. Scan & haemagglutination test.

OPERATION

The patient was scheduled for surgery. On exploration of abdomen, large locular, cystic swelling was present in right lobe of liver which had very close relation with the wall of gall bladder. Other abdominal viscera were normal. The abdominal cavity was packed with formalin soaked sponges to prevent the spillage of scolices into peritoneal cavity. After injection of 10% formalin, cavity of cyst was opened up, the hydatid fluid sucked out, daughter cysts removed, walls excised and haemostasis secured (Fig 2). The cavity closed by approximation of walls and by applying stitches. Two suction drains kept. A part of the wall of the hydatid cyst had to be left in because it had very close approximation with gall bladder.

The microscopic examination revealed a cyst wall which was laminated and acellular. There was germinal layer on one side of cyst wall.

POST–OPERATIVE COURSE

On the first post operative day, patient developed tachycardia. Her pulse rate was 150 /min. The consultant cardiologist was requested to examine her and according to his view there was left axis deviation and poor R wave progression in chest leads I–IV. It was probably due to decreased tidal volume and low alveolar ventilation. She was encourged to take deep breaths. She was started on Tab. Inderal 20 mg t.i.d. Her other post operative envents are summarised in (Fig 3).

Fig: 2. Daughter cysts and wall of cyst

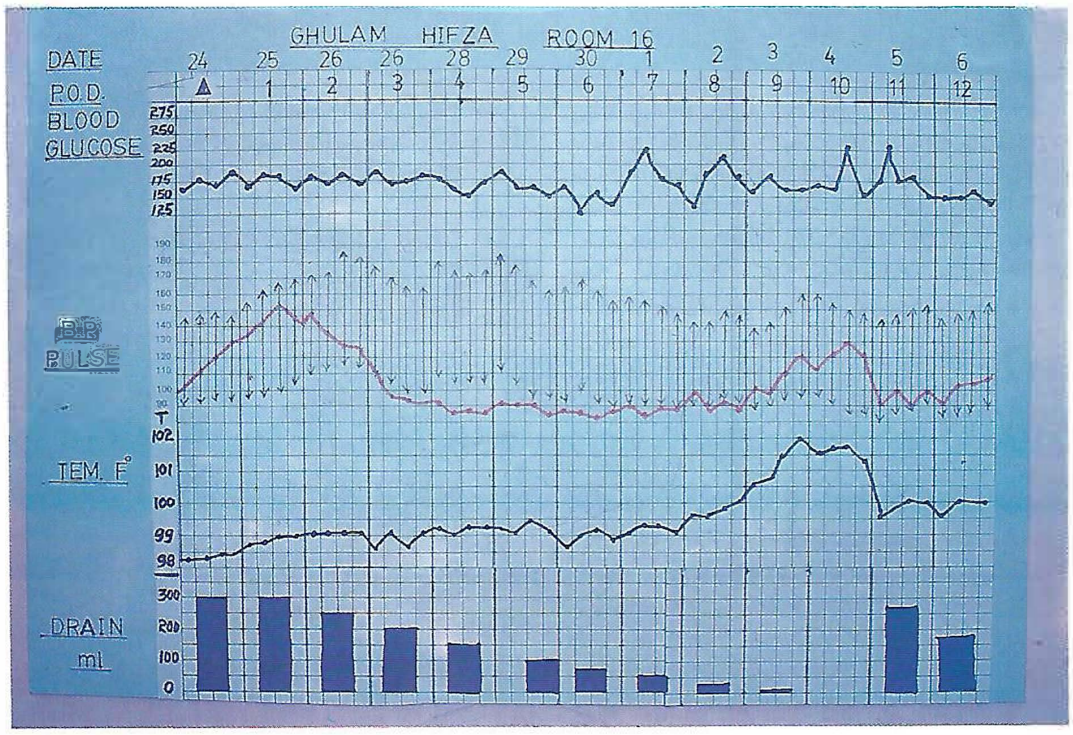

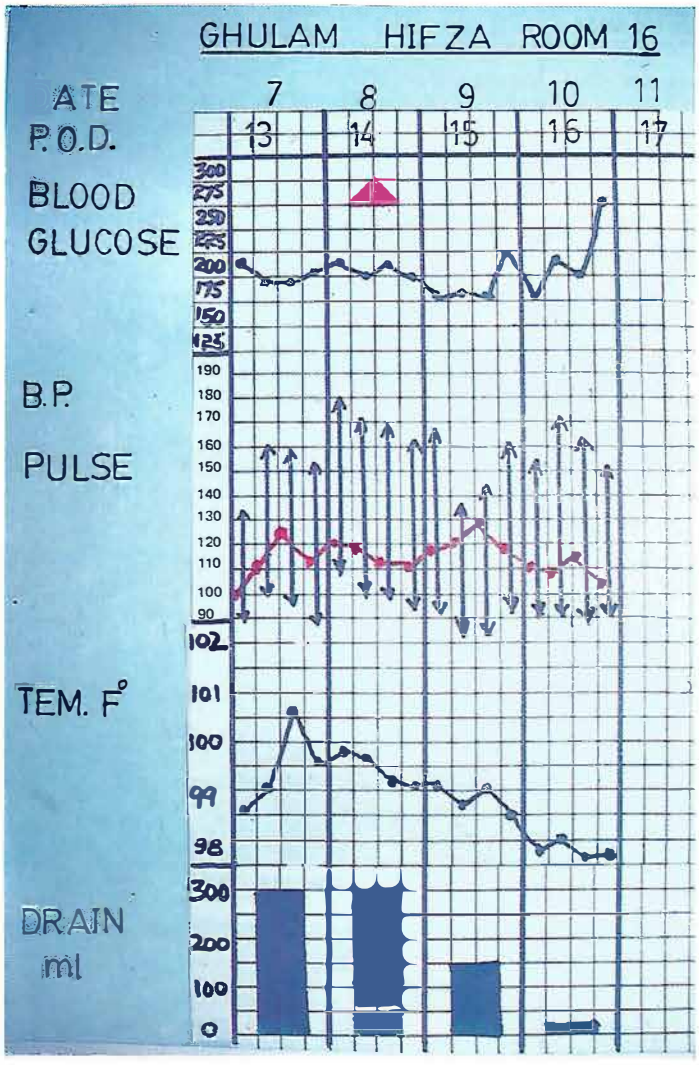

Fig: 3. Parameters during recovery.

She had a smooth recovery till the 8th post operative day when her pulse rate started going up. Her blood glucose fluctuated bewteen 120 & 240 mg/dl at the same time. She complained of pain in her right upper quadrant of abdomen. On examination she was tender in her right hypochondrium. A sub-diaphragnatic collection was suspected. Part of wound was opened and about 300 ml of bile stained fluid drained. An x-ray chest was taken and it showed elevation of right hemidiaphragm and slight pleural effusion (Fig 4)

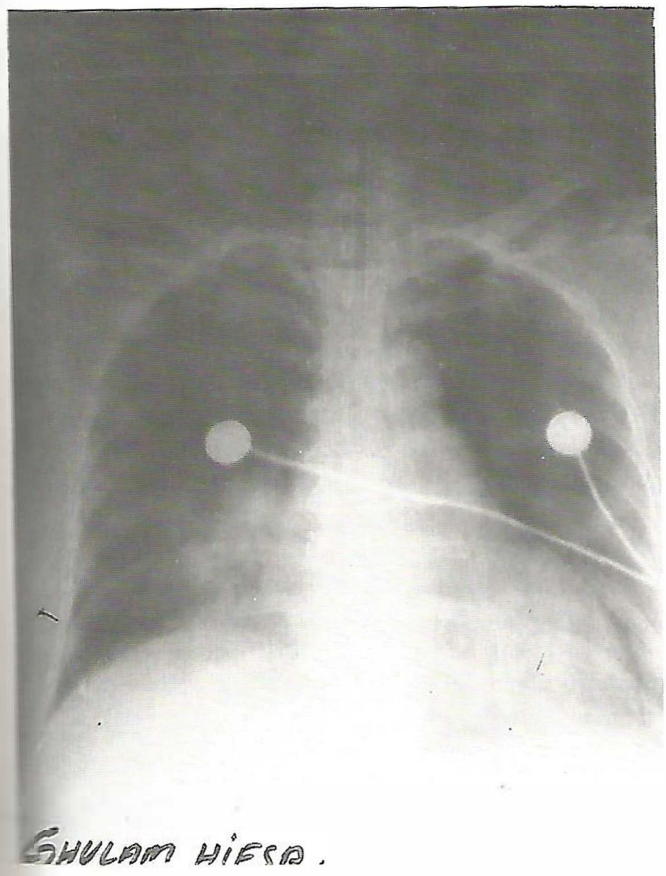

Fig: 4. Post operative X-Ray chest showing raised of right hemidiaphragm and mild pleural effusion.

Decision was made to open her again on the 14th post operative day because a bilary leak was suspected. Under general anaesthesia, the abdomen was opened again through previous incision. The cavity of cyst had small opening through which bile was leaking. The opening was over sewed. Two large size suction drains applied & abdomen closed.

Postoperatively she developed aspiration pneumonia. She was shifted to I.C.U. & put on respirator. Her further management in I.C.U. is discussed later.

DISCUSSION

The hydatid disease is the problem of sheep grazing areas of world, e.g. South America, countries of Southern Europe, Iraq, Pakistan, India and Australia.

The adult worm lives in the intestine of carnivorus animals, usually dogs. It has four segments. The head is the first segment while the last segment is gravid. The embryonated eggs are released and contaminate the faeces of dogs. These faeces are laid on grass and vegetable which is eaten up by sheep & cattle. The onchosphere is released which penetrates the intestine, is carried away by the circulation & develops into hydatid cyst. When the viscera of these cattle are ingested by carnivorus animals, scolices are released and develope into adult worms. The cycle goes on and on. Occasionally man becomes the host of disease. When eggs are ingested, onchospheres are released in the intestine, enter the circulation, settle in various viscera and develops into hydatid cyst. In 60% of cases, it involves the liver & in 20% of cases, the lungs. No part of body is immune to it. It may involve spleen, bones, muscle, cerebrum & eyes.

The cyst wall consists of three layers. The outer most is ectocyst, which is actually the compressed parenchyma of the organ in which hydatid cyst lodges. Second is proteinacious layer which is secreted by the germinal layer. Both these layers are non living. The inner most layer is the germinal layer, which is the only living part of hydatid cyst. It proliferates & forms brood capsules, which contains scolices. The brood capsules disintegrate to form hydatid sand.

When the disease is well contained by body defence mechanism, there is death of csyt, all contents of cyst are changed into tooth paste like material. It is more common in people above 60 year of age. When there is involvement of biliary tree, patient may present with obstructive jaundice. Some time, hydatid cyst ruptures into hepatic venous system and there is dissemination of disease. When there is rupture into peritoneal cavity, the patient may present with anaphylactic shock. The hydatid cyst may erode through lungs & bronchial tree, form bronchio-biliary fistula and patient may actually cough out the daughter cysts. When there is involvement of bare area of liver, the disease penetrates into retro-peritoneal planes and patient may present with swelling in pelvis or inguinal region.

CLINICAL FEATURES:

60–70% patients present with right upper quadrant pain, 30–40 present with hepatomegaly while obstructive jaundice is present in 15% of cases. Anaphylactic attacks,

pruritus, rashes and spontaneous rupture of liver are present in lesss than 10% of patients. 20–35% cases do not have any complaint.

DIAGNOSIS

It is confirmed by immunological methods & organ imaging. The intra-dermal test, known as Casoni's test, was first to be described. Its accuracy rate is about 70 per cent. It has both false positive and negative results. Indirect haemagglutination test, latex agglutination test and complement fixation test are used for screening population now-a-days, in advanced countries. Indirect flourescent antibody test, counter immune electrophoresis, double diffusion test and ELISA are more sensitive tests. The accuracy rate is above 90% and these are used for confirmation of diagnosis.

When the walls of cyst are calcified, the cyst is visible on plain radiograph. The ultrasound is very sensitive and non invasive technique. It can detect lesions above 2 cm in diameter. The C.T. Scan is more sensitive technique and can detect lesions above 1.0 cm in diameter. ERCP is very useful when patient presents with obstructive jaundice. Angiography is very sensitive technique but indicated only when disease has close relationship with big vessels. Radio-isotope scanning is another but less sensitive modality.

TREATMENT DECISIONS

When patient is fit, having large cyst, containing clear fluid, the treatment of choice is excision. However when cyst is very small, it is deeply seated and patient is above 65 years of age, or it is calcified, surgery is better avoided.

COMPLICATION OF SURGERY

Prolonged drainage more than 21 days is present in 25% of patients. Subpherenic abscess develops in 12-15% of patients. Lower lobar collapse and chest infection is present in 5–10% of cases. Post operative mortality is 2–10%, according to previous status of their health. In 5% of cases disease recurs.

CHEMOTHERAPY

The role of chemotherapy in treatment of hydatid disease is still not established. Till now, surgery is the definitive treatment. Mebendazole, flubendazole and albendazole have been showen effective in vivo as well as in vitro. These should be used only in patients who are inoperable, there is spillage of scolices into the peritoneal cavity during surgery and patients who are not willing for surgery.

DR. TALAT *(Anaesthestist)*

I would like to mention the risk factors present in this patient. She was a very obesce lady. It is well known fact that ventilation perfusion abnormalities are definitely higher in obesce patients, as a result of reduced expriatory residual volume and chest compliance. In the immediate post operative period, there is deterioration of pulmonary functions among the obesce patients.

Our patient was diabetic and poorly controlled. Her hypertension was uncontrolled throughout the post operative period & intra-operative period. She also had sinus tachycardia. She had second exposure to gen. anaesthesia on 14th post operative day. This was another factor leading to her admission in I.C.U.

Intra-operatively she didn't give us problem but in the immediate post operative period, after extubation, she had severe bronchospasm and started becoming blue. She was reintubated. She was unable to maintain her gases therefore she was shifted to the I.C.U. and put on a respirator, on controlled mechanical ventilation (CMV). The inspiratory oxygen content was 60% which was reduced to 30%.

The immediate x-ray chest showed aspiration pneumonia. Serial blood gas analysis were carried out. Serial chest x-ray, serum electrolytes, biochemical examination of blood and blood counts were done daily throughout her stay in I.C.U.

On her admission to I.C.U., her PCO_2 was 61mm and PO_2 81mm Hg. She had to be kept on CMV (Controlled Mechanical Ventilation) for next two days because she was not maintaining her blood gases. On the third day weaning started. She was put on SIMV (Synchronized Intermittent Mandatory Ventilation) then switched over to EMMV (Extended Mandatory Minute Volume) but her PCO_2 started rising and PO_2 going down. She was switched-back to CMV.

On fourth post operative day after 2nd surgery, she was again switched over to SIVM at FIO_2 of 35%. This time she could maintain her gases.

On 5th day, she was gradually shifted to spontaneous ventilation and she was able to maintain her blood gases very well at FIO_2 of 30%. She was extubated on 7th day.

COMPLICATIONS OF PROLONGED MECHANICAL VENTILATION.

Firstly mechanical problems, i.e, electricity failure and lack of continuous supply of compressed air. Secondly there could be blockage of endotracheal tube by kinking or by dried sputum. There could be pressure ulceration of mouth, vocal cords, nose or trachea. Patient could have sputum retention and chest infection, inadequate humidification and bacterial contamination. There could be hypotension due to CO_2 washout and raised intra-thoracic pressure. Many patients on prolonged ventilation start G.I. bleeding due to immobilization. They could develop anaemia as a result of malnutrition, G.I. bleeding DIC or blood loss due to numerous blood tests done on them during their stay in ICU. The empyema, pneumothorax, water and sodium retention, with pitting odema are other complications and finally psychological disturbance of patient.

WEANING:

It is usually easier to put a patient on ventilator than to take him off. It is the process of re-establishing adequate spontaneous ventilation and may take anything from minutes to weeks. It is indicated when original disease process has been carried to a stage where the patient is able to fulfill the criteria for weaning.

Firstly, the clincal status of patient's central nervous system. He should be conscious and able to communicate with outer world. Cardiovascularly, he should have good tissue perfusion and absence of dysrrhythmias. As regards Respiratory system, there should be spontaneous minute ventilation of at least 15 ml/Kg of body wt. and should be less than 10 liters per minute. The tidal volume should be atleast 5–7 ml/Kg and respiratory rate should be less than 30 per min. He should be able to maintain his blood gases when switched over to room air. The x-ray chest should be clear. The metabolic status of the patient should be stable.

Weaning is achieved by gradually increasing the [illegible] of spontaneous breathing. The whole process is [illegible] explained to the patient to get full cooperation from him. There should be very good nursing and medical staff available because it is very risky period and any thing can happen. The sedatives and muscle relaxants are stooped and patient is encouraged to breath spontaneously. He is watched carefully for any signs of respiratory distress. The initial period of spontaneous breathing should be 10–15 min. If there is adequate tidal volume and min. ventilation, the interval should be increased to 30 min. and than one hour, or prolonged as necessary. The extubation should follow the successful weaning.

PROFESSOR ASHFAQ *(Cardiologist)*

I have been closely associated with management of this patient, mostly in the post operative period. I was also called earlier to make pre-operative assesment. She was known diabetic and hypertensive. She was high risk patient because she was grossly obesce. Although she didn't. have any clinical manifestation of active heart disease or cardiovascular decompensation but in post-operative period, it was quite well expected. She was lucky to come out from first gen. anaesthesia. It was controlled easily. The problem we faced was after second surgical intervention. I totally agree that she had aspiration pneumonia which further reduced her ventilatory capacity.

The tranquilizers and sedatives can produce significant drop in the respiratory drive. In patients with decompensated systems, these can produce marked reduction in the tidal volume. These should be avoided as much as as possible.

The hypokalemia is an important finding in ICU. It can paralyze respiratory muscles easily, osserum potassium level should be monitored carefully.

Some antibiotics like aminoglycosides have toxic effects on the peripheral nerves; these should be used as little as possible.

This patient had mild diabetic neuropathy which can add to the weakness of respiratory muscles.

When a patient is intubated and put on mechanical ventilation especailly on PEEP (Positive End Expiratory Pressure), there is reduction in venous return. The patient is cardiovascularly decompensated and developes signs of heart failure. If they become dehydrated and there is reduction of intravascular volume, it becomes another precipitating factor. These patients should have a CVP line to monitor central venous pressure while they are kept on ventilator.

DR. QURESHI *(Pathologist):* As for as the pathological diagnosis of hydatid cyst is concerned, on gross examination, the daughter cysts are very characteristic. These are very Iuscent, transparent, delicate and can be ruptured easily because these are very fragile. On opening the cyst, the fluid is very clear, serous and watery. The most important is the wall of cyst. It is one mm in thickness while germinal layer is 20–30 micron. The wall is laminated because it has multiple layers, doesn't take any stain, is acellular exept germinal layer in which we can see multiple nuclei.

The hydatid sand can be present with the daughter cysts which consist of scolices. The scolices are acid fast.

When the cyst ruptures, there is tremendous granulomatous response and one may confuse it with tuberculosis. The scolices are birefringent under polarised light, so these can be differentiated from mycobacterium tuberculosis.

DR. SADDIQI *(Radiologist)*: When we suspect hydatid cyst in a patient, the first investigation is plain x-ray abdomen and chest. If cyst is calcified, it is out lined. If there is no calcification, we can still appreciate enlarged liver shadow, which will be associated with raised right hemidiaphargm and downward displacement of hepatic flexure of colon. The renal shadow might also be displaced.

The next diagnostic modality is ultrasound which can demonstrate and enlarged liver with the characteristic findings of multiple, locular cystic areas. One has to differenciate from a solitary cyst which has smooth thin walls. In Hydatid cyst, the multiple areas are clumped together and cysts have characteristic thick walls.

The radio-isotope scan will depict a filling defect which can be due to a cyst, an abscess or any other space occupying lesion.

The C.T. Scan is very valuable. It shows locular areas, thick walls which are not well defined as compared to simple cysts. The C.T. Scan is almost diagnostic in lesions above 2 cm in size.

DR. SAEED (FCPS Part 2 *student)*:: In this patient formalin was used as scolicidal agent. What are the side effects of formalin?

DR. PERVAIZ: The most important side effect of formalin is sclerosing cholangitis when formalin gets into biliary radicals of if cyst is communicating with it. It is present in less than 1% of patients. It may ultimately cause cirrhosis of liver after a few years. This drug has been used in many countries for ages because it is cheap and easily available in sterile condition. We had to use it because we had no other choice at that time.

DR. IQBAL *(Pulmonologist)*: She was very high risk patient. If her diabetes and hypertension were not controlled, would she be subjected to surgery, this is the point to ponder. There comes the medical treatment of hydatid cyst. Mebendazol has been tried at various centers. It has definetly reduced the doubling time of hydatid cyst. It should be tried in all high risk patients before sugery. The patients above 70 years of age, who have multiple cysts are also good candidates for conservative management.

Half per cent cetramide is very good scolicidal agent. Its effectiveness is universally accepted. At Al-Khamini Hospital Tehran, where about 20–30 hydatid cysts are taken out from live and 10–12 cysts from lungs yearly, it is the drug of choice. I strongly recommend this drug as scolicidal agent for future use in our hospital.

Post-operatively, all obesce patients should get good physiotherapy of chest to get rid of the secretions. The prophylactic tracheostomy in obesce and old patients reduces the chances of aspiration pneumonia.

DR. PERVAIZ *(G.P. Lahore)*: I would like to know about the biliary fistula, as a complication of hydatid disease surgery.

DR. DURRANI *(Gen. Surgeon)*: The complication you have mentioned has been well documented and there are certain precautions we should take, while operating on a case of hydatid cyst. The most important, step while aspirating, one has to make sure that the cyst has no communication with biliary canaliculi. If the contents of the cyst are bile stained, then cyst is dissected very carefully and biliary radical is isolated and closed down meticulously. In some patients, where the biliary radical is quite extensive, one has to perform hepaticojejunostomy, by bringing a loop of intestine close to liver and anastomosing it with the biliary opening on the raw surface of liver. The biliary fistula is a common complication of liver surgery. Incidently, this patient also developed biliary fistula, she had to be opened again and fortunately we were able to identify the biliary opening. It was over sewed and there after she had no discharge.

DR. TARIQ: Is there any role of needle aspiration in the treatment of hydatid disease ?

DR. DURRANI *(Gen. Surgeon)*: I think needle aspiration should be condemned. If immunological tests are positive in patient with enlarged liver or a hydatid cyst is suspected on ultrasound, needle aspiration is contraindicated.

DR. NAJEEB *(biomedical Engineer)*: In this patient, only IMMV was practiced. I think more is to be done in view of choosing other modalities particularly High Frequency Jet Ventilation. It is very useful in septicemia where suction is required. It can also be superimposed on spontaneous ventilation without intubation. As Prof. Ashfaq mentioned about cardiac output problem, it has

been shown that high frequency jet ventilation, synchronized with heart rate can do away with the buildup of positive intrathoracic pressure and reduced cardiac output.

DR. HADI: Why was cholecystectomy not performed in this patient considering that wall of cyst was in close relation with gall bladder ?

DR. DURRANI: *(Gen. Surgeon):* There was no indication for cholocystectomy because sergeons don't want to complicate their operative procedures espacilly in this patient who had all types of problems associated with simple hydatid cyst. At this stage, I want to mention that this was not the only case we have taken care of. In the last 6 months we have treated 7 cases of hydatid cyst but we have picked up this patient because this was the one which gave us problems. All other operations were very successful, patients had uneventful recovery and went home.

This patient, to begin wth, had problems of obesity, uncontrolled diabetes mellitus and hypertension. She had some post-operative complications as well, so we selected this patient for discussion.

As regards the surgical management of hydatid liver cysts, there are views about total aspiration of cyst and excision of intact cyst. However the majority favour the total aspiration, as it is safe and can be carried out adequately if precautions are taken to prevent the spillage of contents into peritoneal cavity. A thorough exploration of cyst wall should be done for small cysts that may be attached to the cyst wall, otherwise recurrence is likely.

It the contents of cyst are bile stained, it is highly likely that the main cyst is dead. Though viable daughter cysts may still remain in its recesses. About the scolicidal agents, the choice is between 0.5% silver nitrate (freshly prepared), 0.5–1% cetrimide or hypertonic saline. As for as the method of aspiration goes, the Australians have devised a special cone (Aarons cone) or lately the cryogenic cone, which can be held in place by theatre suction over the point of opening of the cyst wall.

The communication of the cyst wall with a biliary radicle poses some problems. It is advisable to pack clean dry sponges firmly into the remaining cyst, remove after 5 min. and examine for any bile staining. Once identified the leak must be closed meticulously.

The excision of the cyst (cysto-pericystectomy) has been advocated by some workers but it is a much more demanding procedure and is associated with high risk of bleeding. The obliteration of cyst cavity can be achieved by omentoplasty or by filling of the cyst with saline and suturing back its walls.

The infected cysts are dead but need evacuation and external drainage.

Small intra-parenchymal cysts can be safely watched by repeated scanning. Once the cyst has reached a subcapsular position, complications are likely, hence surgery should be undertaken.

About the recurrence of hydatid disease, the average incidence in the literature is 10% but it varies in different series. Three most important causes of recurrence are small cysts missed at first operation, spillage and reinfection.

The surgical treatment of hydatid disease is associated with a mortality around 3–5% and some morbidity which is increased in high risk patients.

REFERENCES

1. Bekhti A, Schapps JP, Capron M,et al: Treatment of Hepatic Hydatid Disease with Mebendazole: Primary results in four cases. *Br. Med. J.* 1977; 2: 1047.
2. Debakey ME, Jordan GL: Surgery of Liver P. 1103, in *Diseases of the Liver* 4th ed. Lippicott, Ohiladelphia, 1975; 1033.
3. Macris GJ, Galanis NN: Rupture of echinococcus cyst of liver into biliary ducts. *Am. J. Surg.* 1966;32:36.
4. Schillar CF: Complications of echinococcus cyst rupture *JAMA* 1966; 195:220.
5. Morris DL. Pre-operative albendazole therapy for hydatid cyst. *Br. of Surg.* 1987; 74:9.
6. Kune GA. Hydatid disease in, Schwartz SI., Ellis H. (eds) maingot's abdominal operations, 8th ed. Norwalk Appleton Century Crafts, 1985.
7. Aarons BP., Fitz Patrick Sc.:Hepato-biliary h
7. Aarons BP., Fitz Patrick Sc.:H
7. Aarons BP., Fitz Patrick Sc.:Hepato-biliary hydatid disease, in Kune GA., Sali A. (eds), *The Practice of Biliary Surgery;* Oxford Blackwell 1980.
8. Smego R.A, Smego DR, Management of human Echin ococcos: *Patistan Journal of Surgery,* 1987; 3: 29-34.