

# Surgery for Cushing's Syndrome

M. Ayub Khan, Khalid Durrani, Shahid Omar

Department of Surgery and Endocrinology, Shaikh Zayed Hospital, Lahore

## INTRODUCTION

Cushing's Syndrome represents a constellation of signs and symptoms resulting from excess of cortisol. Iatrogenic disease as a result of the administration of glucocorticoids, is by far the most common cause<sup>1</sup>. Excessive secretion of corticotropin from pituitary or extrapituitary tumors, constitute the second common cause (Pituitary disease). Finally Cushing's Syndrome may be the result of primary adrenal disease i.e. adrenal adenoma, adrenal carcinoma and primary bilateral nodular adrenal hyperplasia.

We present a young female with Cushing's syndrome due to adrenal adenoma, who was successfully treated by adrenalectomy.

## CASE REPORT

Miss N.P. is a young girl of 25 years who presented to medical out patient department in July, 1990 with two years history of gradual weight gain, puffiness of face, cessation of menstruation, hirsutism and dark coloured rashes over abdomen and legs.

On examination she was an obese, moon faced young girl having hirsutism. She had a typical buffalo hump. (See Fig No. 1 & 2). Her B.P. was 150/110 mmHg pulse 80/min.

Her abdomen was protuberant, multiple striae were found on lower abdomen, trunk and upper legs. The systemic examination was nonrevealing. The patient was found to have hypertension and was admitted to the Cardiology department for the control of blood pressure. Her B.P. was controlled on Tab. Inderal.

The patient was investigated. The Lab. data revealed Hb. 13.9 mg/dl, serum electrolyte, renal profile and LFT's were within normal limits. A provisional diagnosis of Cushing's Syndrome was made and patient was worked up on that lines.

24 hours 17 Ketosteroid 27.9 mg (N.V = 6 - 12 mg/24 hour)  
Plasma cortisol (Mor) 31.95  $\mu\text{g}\%$  (N.V = 6.5 - 16  $\mu\text{g}\%$ )

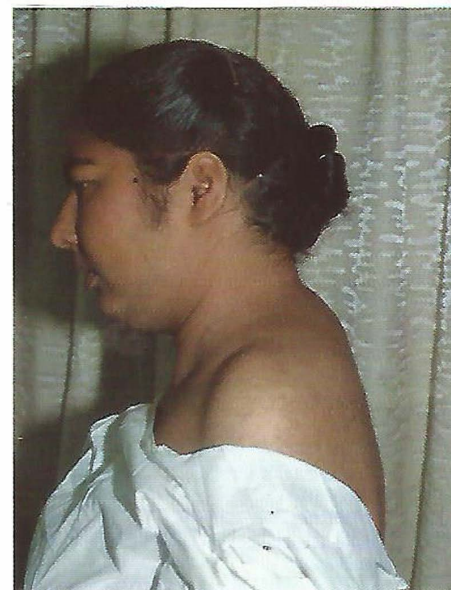
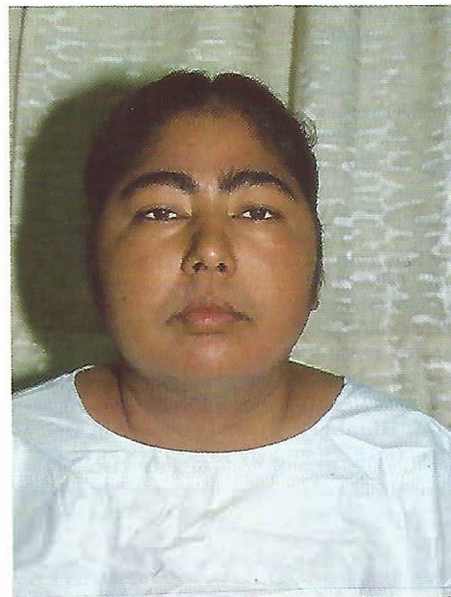
Fig. 1: Pre-operative picture moon faced, hirsutism and buffalo hump.

Radiological skeletal survey did not show any bone changes. Her U/S abdomen and C.T scan revealed a well defined rounded soft tissue density mass about  $12.5 \times 2.4$  cm in the right adrenal area. So based on above lab. data and C.T. findings a diagnosis of

adrenal cortical tumour was made and the patients was scheduled for surgery. On 17th October, 1990 the patients was operated. On exploration through a right transcostal incision (11th rib) right adrenalectomy was performed A 5 cm size oval brownish coloured tumour was found in the right adrenal gland. (See Fig 3). The specimen was sent for frozen section which was reported to be a right cortical adrenal adenoma.

Pre-operative steroid therapy as given in Table I.

**Table 1: Pre-operative steroid therapy.**

Inj. Solucortef 250 mg I/V stat at induction.
Inj. Solucortef 250 mg I/V infusion over next 12 hours.

**Post Operative Period.**

In the immediate post operative period her B.P went up to 180/120 which was controlled with the cap. Adalat. Rest of the post operative period was smooth and uneventful.

Post operative steroid replacement therapy was given as shown in table II. Patient discharged on 23-10-90 in a satisfactory condition with steroid replacement dose of Tab. Prednisolon 7.5 mg/day.

**Table 2: Post-operative steroid therapy.**

Inj. Solucortef 100 mg x 8 hourly I/M x 2 day
Tab. Deltacortil 5 mg.
1 Tab. t.i.d x 2 days
1 Tab. b.i.d x 2 days
1 + 1/2 (7.5 mg/day)
At the time of discharge
The dose tapered off gradually.


**Histopathology**

Section shows thinly encapsulated mass composed of mainly zona glomerulosa cells and some zona fasciculata cells. There is no nuclear pleomorphism and no mitosis are seen. There is no evidence of haemorrhage or necrosis or of vascular invasion. The capsule is also not infiltrated by tumor. These appearances are of adrenal cortical tumor most likely to be an adenoma as the weight is 52 gms and 5 cm in maximum diameter.

**Follow up**

The patient was jointly followed up by the department of General Surgery and Endocrinology to date.

Her steroid replacement therapy gradually tapered off. Her B.P was well controlled without any medication. She had gradual loss of weight and redistribution of her fat deposition. Her hirsutism disappeared and she resumed her menses. (See Fig No. 4 & 5). She got married 6 months after surgery and enjoys normal life. One year after surgery she is off all medications.



**Figs. 3-4: Post-operative picture. Loss of weight, redistribution of fat and disappearance of hirsutism.**

## DISCUSSION:

The origin of Cushing's Syndrome can be evaluated by high dose dexamethasone suppression test. Patients with primary adrenal disease and Ectopic Corticotropin production, will not suppress urinary 17-hydroxycorticosteroids and cortisol. Measurement of corticotropin will help to further delineate these groups. Primary adrenal disease causes suppression of corticotropin release (Low levels). Pituitary disease produces moderately high levels and A.C.T.H is very high with ectopic source<sup>2</sup>.

Radiological studies help to confirm and localize the source of hypersecretion of cortisol C.T of the abdomen will identify and localize the primary adrenal disease (Adenoma & adrenal carcinoma). Benign adenomas are usually < 5 cm. However 30% adenomas are between 5-7 cm. (3). The adenoma in the above reported patient was 5 cm. in size.

Adrenal surgery became feasible after the discovery of cortisone, in the late 1940's. Preoperative cortisone is required for patients undergoing total bilateral adrenalectomy, or unilateral adrenalectomy, because of the suppression of the contralateral gland. Replacement therapy is to be continued post operatively for a period of 3-6 months<sup>4</sup>.

Surgery of the adrenal gland for adrenal adenoma, usually have excellent results. The survivors after adrenalectomy for adenoma, can expect 100% clinical and endocrinological cure<sup>1,5</sup>. The physical signs of Cushing's syndrome, disappear within a year. The above patient resumed normal appearance and menstruation by the end of 9 months.

## REFERENCES

1. **Bloom LS, Libertino LS.** Results of Adrenal Surgery for Cushing's Urologic Clinics of N. America, **16**: 547-565, 1989.
2. **Bergland RM, Gonn DS, De Maria EJ.** Pituitary and Adrenal in Schwartz SI Ed. Principles of Surgery, 5th Ed. Singapore McGraw Hill PP. 1560-1583, 1990.
3. **Watson RG, VanHearder JA, et al.** Results of adrenal surgery for Cushing's Syndrome 10 years experience. *World J Surgery* 1986; **10**, 531-8.
4. **Wellbourne RB.** Operations on the Adrenal Gland. in Dudley H, Pories W.J. (Eds). Rob and Smith's Operative Surgery Edition 4, London Butterworth Scientific PP 397-414, 1982.
5. **Schwartz RJ, Schmidt N.** Efficient Management of Adrenal Tumors. *Am J Surgery* 1991; **161**: 576-9.

### The Authors:

M. Ayub Khan,  
Department of Surgery  
Shaikh Zayed Hospital,  
Lahore.

Khalid Durrani,  
Department of Surgery  
Shaikh Zayed Hospital,  
Lahore.

Shahid Omar  
Department of Endocrinology,  
Shaikh Zayed Hospital,  
Lahore.

### Address for Correspondence:

M. Ayub Khan,  
Department of Surgery  
Shaikh Zayed Hospital,  
Lahore.