

An Unusual Case of Failure to Thrive

Waqar Hussain, Nasim Mahmood, Prof. Sajid Maqbool
Department of Pediatrics, Shaikh Zayed Hospital, Lahore

SUMMARY

Congenital diaphragmatic hernia usually presents in neonates. A small number of cases, however remain clinically silent and may present late or are discovered accidentally. We describe a case of congenital diaphragmatic hernia with intrathoracic liver in a 9 month old infant who presented with failure to thrive.

CASE

A 9 months old male child presented with the complaints of failure to thrive. Feeding had been inadequate because of fatigue on sucking. He developed noisy breathing at 5 months of age and was treated for repeated respiratory tract infections without a specific diagnosis. Physical examination revealed that his height and weight were below the third percentile. He had noticeable intercostal and subcostal retractions, although movements of the chest were symmetrical bilaterally. There was a dull percussion note and reduced air entry on the right side of the chest but no signs of mediastinal shift were elicitable. Liver could not be palpated.

X-ray chest showed obliteration of right lung field with uniform opacity occupying the middle and lower zones. The right hemidiaphragm was not visible (Figs. 1 and 2).

An ultrasound examination confirmed high intrathoracic liver with poorly visualized right hemidiaphragm. The right lung showed collapse without evidence of pleural effusion.

DISCUSSION

The diaphragm develops from septum transversum, pleuroperitoneal membrane and dorsal mesentery of oesophagus. Fusion of these elements obliterates the posterolateral pleuroperitoneal canal (Bochdalek Foramen). Defective obliteration of the canal leads to Bochdalek posterolateral diaphragmatic hernia. It is differentiated from "central hernia" (split through costal and sternal origins of the diaphragm) and herniation through

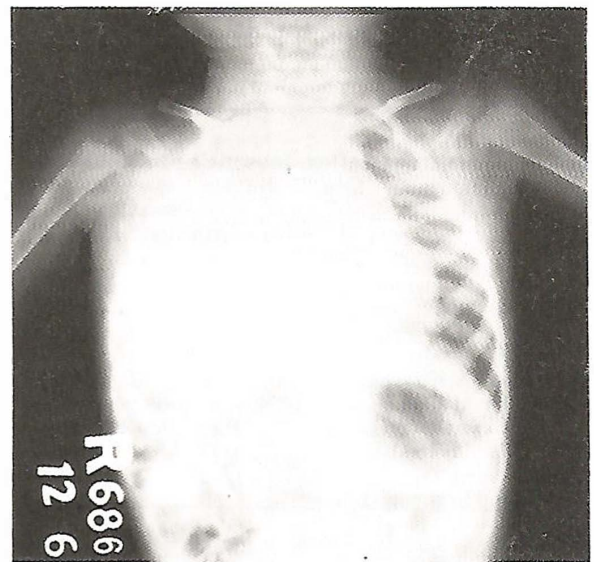


Fig. 1: X-ray chest (AP view) showing uniform opacity of right middle and lower zones. Right hemidiaphragm is not visible.

the foramen of Morgagni (failure of fusion of two analges of diaphragm in the midline). Hernia is to be differentiated from eventration which is a fibrous membrane replacing the diaphragm. Absence of discontinuity differentiates eventration from hernia¹. Left sided diaphragmatic herniae are generally more common, the left to right ratio being 2.5:1².

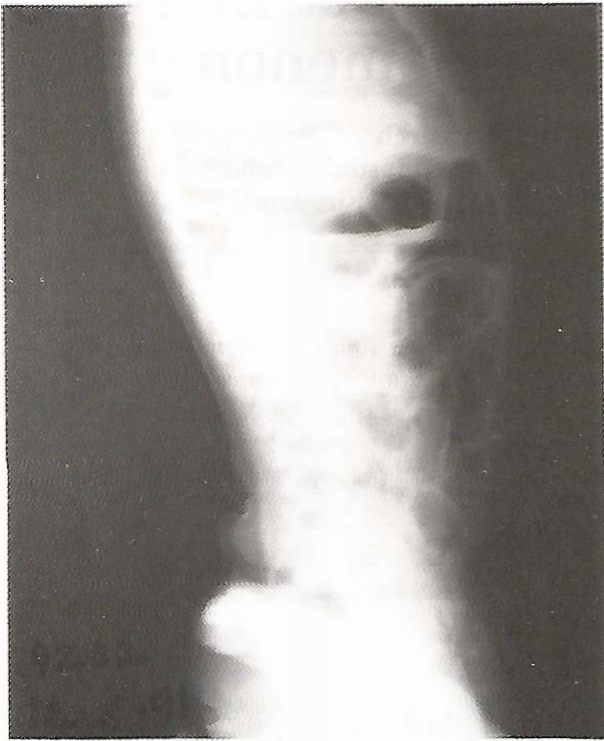

Fig. 2: X-ray chest (lateral view).

According to Malon et al², the most common presenting feature of herniation of the liver diaphragmatic hernia is failure to thrive as was indeed found in our case. Other modes reported are abdominal pain, vomiting, chronic respiratory symptoms or in instances, no symptoms at all. The condition is suspected when the diaphragm is not clearly visible on X-ray³.

Conditions that can simulate and lead to misdiagnosis are pleural effusion, atelectasis and pneumonia. Various methods have been recommended to evaluate the integrity of the diaphragm. These include Barium meal examination, ultrasound, radio-nucleotide scanning of the liver and spleen, umbilical venography, C.T. Scan, contrast peritoneography and diaphragmatic screening. Barium study and ultrasound are helpful in ventilated patients.

Right sided diaphragmatic hernia with intrathoracic liver is extremely rare, and only a few cases have been reported so far. Possibly the liver on the right side plugs smaller defects, thus preventing herniation.

The prognosis is considered better is those presenting late compared to those presenting

earlier¹⁻⁷. However, cases have been reported which demonstrate that undiagnosed diaphragmatic hernia in previously healthy infants may have a lethal outcome i.e. collapse and death⁸.

CONCLUSION

Congenital diaphragmatic hernia, especially right sided defects present late resulting in diagnostic delay and inappropriate treatment. A child with failure to thrive and repeated chest symptoms may have an underlying diaphragm defect. In these cases integrity of diaphragm should be confirmed.

REFERENCES

1. **Bonham, Carter RE, et al.** Hernia and eventration of diaphragm in childhood. *Lancet* 1962; 1: 656-9.
2. **Cunniff C, et al.** Patterns of malformation in children with congenital diaphragmatic hernia. *J Pediatrics* 190; 116: 258-61.
3. **Malone PS, et al.** Congenital diaphragmatic defects that present late. *Arch Dis Child* 1989; 64: 1512-11.
4. **Wiseman NE, et al.** Acquired congenital diaphragmatic hernia. *J Ped Surg* 1977; 12: 657-65.
5. **Ruff SJ, et al.** Pediatric diaphragmatic hernia - eleven years experience. *Am J Surg* 1980; 139: 611-5.
6. **Graivier L, et al.** Congenital diaphragmatic hernia in children. *Surg Gynaecol/Obstet*, 1971; 132: 408-10.
7. **Roger W. Byard et al.** Unsuspected diaphragmatic hernia- a potential cause of sudden and unexpected death in infancy and childhood. *J Ped Surg* 1990; 62: 1166-68.

The Authors:

Waqar Hussain,
Assistant Professor,
Department of Pediatrics,
Shaikh Zayed Hospital,
Lahore.

Nasim Mahmood,
Registrar,
Department of Pediatrics,
Shaikh Zayed Hospital,
Lahore.

Sajid Maqbool
Professor,
Department of Pediatrics,
Shaikh Zayed Hospital,
Lahore.

Address for Correspondence:

Waqar Hussain,
Assistant Professor,
Department of Pediatrics,
Shaikh Zayed Hospital,
Lahore.