

Insertion of Inferior Vena Caval Filter and Thromboembolic Phenomenon

Farrukh Iqbal, D.R. Prichard*, P.D. Birch*

Department of Medicine, Shaikh Zayed Postgraduate Medical Institute, Lahore and
*Bangor General Hospital, Bangor, North Wales, United Kingdom

SUMMARY

Thromboembolic phenomena are common in the elderly population and their consequences can be life threatening. Although anticoagulants are the mainstay of therapy there are conditions in which their use is contraindicated. Alternative therapeutic options involve the use of more invasive techniques to prevent major thromboembolic incidents. We describe a case in which a modified Greenfield titanium filter was inserted into the inferior vena cava to prevent recurrent pulmonary emboli from iliofemoral venous thrombosis. Anticoagulants were contraindicated due to the presence of a haemorrhagic gastritis.

CASE

A 75 year old gentleman was admitted with a one day history of swelling of his right calf and thigh. The past medical history documented atrial fibrillation and a cerebrovascular accident from which he had made a full recovery. He had also undergone a Billroth type II gastrectomy for chronic duodenal ulceration. Multiple gastroscopies had consistently demonstrated a haemorrhagic gastritis presumed to be due to biliary reflux secondary to this surgery. One month prior to his present admission he had sudden onset of breathlessness without chest pain and a pulmonary embolism was suspected. This was confirmed on a ventilation/perfusion lung scan. He was started on calcium heparin while in hospital vigilantly, but long term anticoagulation was not acceptable.

On this admission his general condition was good. Pulse was 80 per minute, irregularly irregular and the B.P. was 110/70. His JVP was not raised and the heart sounds were normal. Examination of the respiratory, abdominal and central nervous systems was unremarkable. The right leg was swollen, tender and warm.

A clinical diagnosis of right iliofemoral venous thrombosis was made and confirmed by venogram (Fig. 1) and colour Doppler ultrasonography. Full long-term anticoagulation was felt once again to be contraindicated in view of the known haemorrhagic

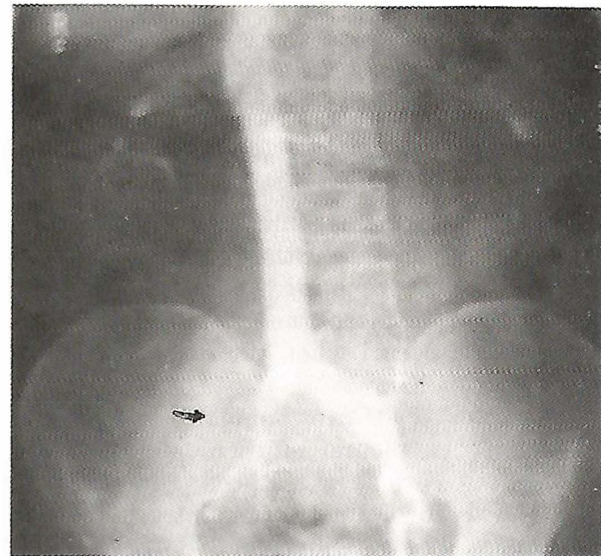


Fig. 1: Venogram - showing obliteration of right common iliac vein (arrow).

gastritis. After extensive discussion with the patient, his relatives and his General Practitioner, a modified Greenfield vena caval filter (Fig. 2) was successfully inserted via a left femoral vein approach. There were no subsequent complications and the patient remains well at two months following insertion. The position of the filter was checked and clots were ruled out in the filter by an ultrasonogram (Fig. 3).

are unreliable². High resolution real-time ultrasonography supplemented by colour Doppler imaging is increasingly accepted as a highly accurate, non invasive technique to establish the diagnosis³.

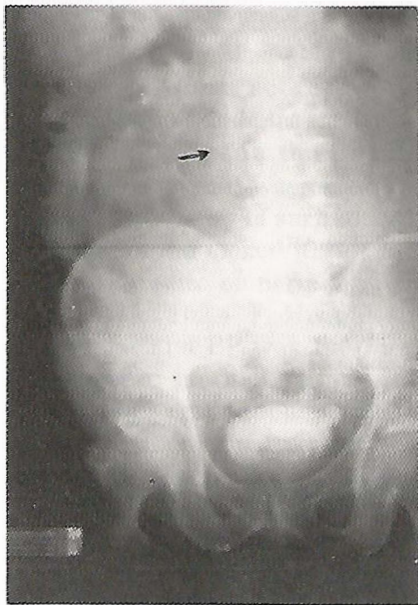

Fig. 2: Kimray - greenfield filter (arrow) in inferior vena cava below the renal veins.

DISCUSSION

Venous thromboembolism is a potentially fatal disease and its incidence has not changed over the last 30 years¹. The proportion of the aged population over 65 years has almost doubled. It is relatively common for patients in this age group presenting with thromboembolism to have a co-existing pathology which precludes anticoagulation e.g. bleeding diathesis, bleeding peptic ulcers, cerebral aneurysms, severe hypertension, severe liver disease, recent eye or neurosurgery, hypersensitivity, confusion and frequent falls. Consideration must therefore be given to alternative treatment strategies.

The diagnosis is often difficult as clinical signs

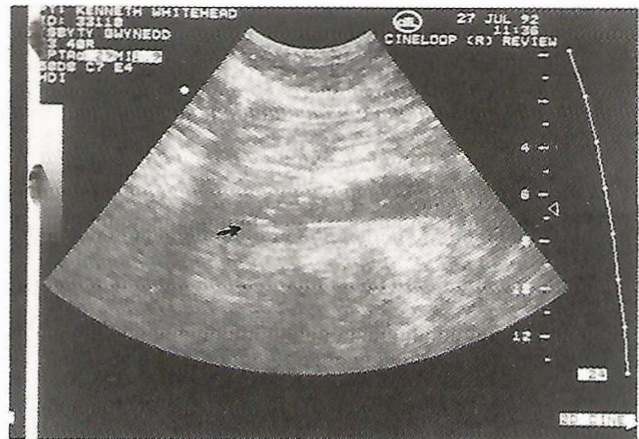


Fig. 3: Ultrasound scan showing prongs of filter (arrow).

Surgical interruption or ligation of the IVC has resulted in significant morbidity and mortality. The use of intra caval balloons and other devices is associated with a high incidence of IVC thrombosis^{1,5}. Vena caval filters were introduced in an attempted to overcome these problems, yet still provide effective trapping of emboli. Of these Kimray-Greenfield filter has gained the widest acceptance⁶. This was originally of large calibre (24 French) and required surgical replacement by a venous cut down. The modified filter allows percutaneous placement by a 12 French introducer system via either the femoral or jugular vein. In our patient the right iliofemoral vein was blocked due to thrombosis, therefore left femoral vein was chosen. With a 12 French introducer system the sheath is introduced up to a point below the renal veins, then it is withdrawn to fully uncover the capsule. Longitudinal axis of the filter should be in the vertical axis of IVC. Once the filter is ejected, the sheath is withdrawn. Compression of the puncture site for 10 minutes is required.

The complications of percutaneous placement of an IVC filter include air embolism, clot formation around the introducer system and filter, and filter

misplacement. The limbs of the filter may also penetrate the wall of the vena cava resulting in retroperitoneal bleeding or perforation into adjacent structure e.g. bowel, ureter and aorta. Delayed complications include occlusion of the IVC which occurs in about 5-6% of patients, filter migration to right atrium or pulmonary artery and infection^{7,8}. None of these complications was encountered in our patient although the limbs of the filter were noted to have opened asymmetrically. This seems to be a relatively common occurrence with this design of filter but does not appear to have compromised its effectiveness in this patients.

ACKNOWLEDGEMENT

We are grateful to Dr. P.N. Ohri Associates Specialist, Dr. L. Roche S.H.O. for their help, and Mrs. M. Dyson for typing the manuscript.

REFERENCES

1. Lindball B, Sternby NH, Bergqvist D. Incidence of thromboembolism verified by necropsy over 30 years. *BMJ* 1991; 302: 709-11.
2. Goldhaber SZ, Hennekens CH, Evans DA, et al. Factors associated with correct antemortem diagnosis of major pulmonary embolism. *Am J Med* 1982; 73: 822-6.
3. Reis SE, Polak JF, Hirsch DR, et al. Frequency of deep venous thrombosis in asymptomatic patients with coronary artery bypass grafts. *Am Heart J* 1991; 122: 478-82.
4. Novelline R. Practical points on transvenous insertion of inferior vena cava filters. *Cardiovasc Intervent Radiol* 1980;

- 3: 319.
5. Simon M, Palestrant A. Transvenous devices for the management of pulmonary embolism. *Cardiovasc Intervent Radiol* 1980; 3: 308.
6. Tadarworthy SM, et al. Kimray - Greenfield vena cava filter: Percutaneous introduction. *Radiology* 1984; 151: 525-6.
7. Prince M, et al. Diameter of the inferior vena cava and its implications for the use of vena caval filters. *Radiology* 1983; 149: 687.
8. Roehm J, Jr. et al. Percutaneous transcatheter filter for the inferior vena cava. A new device for the treatment of patients with pulmonary embolism. *Radiology* 1984; 150: 255.

The Authors:

Farrukh Iqbal,
Assistant Professor,
Department of Medicine,
Shaikh Zayed Postgraduate Medical Institute,
Lahore-54600.

D.R. Prichard,
Consultant Physician
Bangor General Hospital,
Bangor, North Wales,
United Kingdom.

P.D. Birch
Consultant Radiologist
Bangor General Hospital,
Bangor, North Wales,
United Kingdom.

Address for Correspondence:

Farrukh Iqbal,
Assistant Professor,
Department of Medicine,
Shaikh Zayed Postgraduate Medical Institute,
Lahore-54600.
Pakistan.