Proceeding S.Z.P.G.M.I. vol: 17(1): pp. 31-37, 2003.

Management of Carcinoma of Hypopharynx by Laryngopharyngo-Oesophagectomy with Stomach Pull-up

Abdul Hadi, Sarfraz Latif
Department of ENT, Shaikh Zayed Medical Complex, Lahore

SUMMARY

Squamous cell carcinoma of hypopharynx is a relatively rare tumour. There are different treatment options depending upon extent of disease. In this study 20 patients having carcinoma hypopharynx at T3 and T4 stage were treated by total laryngopharyngo oesophagectomy and stomach pull up with or without neck dissection. There were 12 females (60%) and 8 males (40%) with age range 30-60 years. Regarding the nodal status 10 had N1, 5 patients N2 and 5 patients were without nodal involvement. Out-come of surgery was assessed by regular follow-up in ENT outpatient department for 3 years. The results showed that 8 patients (40%) were disease free, 6 patients (30%) were under observation, 4 patients died and 2 patients (10%) lost in follow-up. Immediate complications, 4 patients (20%) had pneumothorax and one patient (5%) had rupture of trachea. Delayed complications noted in our patients, 2 had pharyngogastric stenosis (10%), 2 paitents presented with recurrence of disease. We assessed that total laryngopharygo-oesopharnygectomy with stomach pull up is a procedure of choice for the advanced stage of carcinoma hypopharynx. The procedure offers a significant chance of locoregional control of the disease and early postoperative oral feeding.

INTRODUCTION

The hypopharynx is divided into three sites anatomically, pyriform sinus, the postcricoid area and the posterior pharyngeal wall. The tumours of the hypopharynx represent approximately 7% of all the cancers of upper aerodigestive tract.[1] Carcinoma of the hypopharynx continues to be challenge to the head and neck oncologist. The advanced degree of local invasion, the propensity of lymphatic metastasis to regional and mediastinal nodes and the increased potential for distant occult metastasis, characterizes the usual pathologic state when the patient is first seen.[2]

Majority of the cancers of hypopharynx are squamous cell in type. These tumours are divided according to the three main anatomical regions of the hypopharynx.

Age incidence rate for pharyngeal cancer, show an increased risk of developing the disease with increasing age for both men and women. The peak age for female is 31-35 years while for male it is 55-60 years.[3]

Alcohol and tobacco remain the two principle carcinogens implicated in tumours of the upper acrodigestive tract. Iron deficiency anaemia has been reported to be a major risk factor associated with post-cricoid carcinoma especially in patients with plummer vinson syndrome. Other contributing factors are low serum cholesterol, hot spicy food and in some studies excessive tea consumption.[4]

Hypopharyngeal tumours are asymptomatic while small. The larger tumours may present with progressive dysphagia, pain in throat, hoarseness of voice, haemoptsis, weight loss and sometimes with neck mass.

Small hypopharyngeal tumours without neck nodes (T1-T2 NoMo) are treated primarily with

radiotherapy. Larger tumours involving cervical oesophagus (T3-T4) with or without nodal involvement or cases of radiotherapy failure are treated with surgery.[5] The best surgical option at this stage is the total laryngopharyngo-oesophagectomy with or without neck dissection depending upon nodal metastasis.

Reconstruction after surgery depends upon local extent of disease, general condition of the patient and facilities available.[6] The possibilities for repair are, skin flaps or visceral replacement. The options for skin flaps and visceral reconstruction is, stomach pull up, free jejunal transfer and colonic transposition.

MATERIALS AND METHODS

This study is based on retrospective analysis of advanced carcinoma hypopharynx who had laryngopharyngo-oesophagectomy with stomach pull-up with or without neck dissection in ENT department of Shaikh Zayed Hospital, Lahore in last 3 years. The present data of 20 patients, 12 female and 8 male. All patients were admitted through out-patient department, assessed thoroughly by history, clinical examination, panendoscopy and biopsy under general anaesthesia. Before panendoscopy all necessary lab and radiological investigations done. CT scan advised in affording patients. Staging of the tumour done accordin gto TNM classification. We included the patient having (T3 and T4) stage, who were fit and willing for surgery.

We excluded the patients (who had recurrence of disease after surgery), with distant metastasis and who had previous gastric surgery or local pathology in the stomach. In all these patients the total laryngopharyngo-oestophagectomy with stomach pull-up done with or without neck dissection depending upon nodal involvement. All the 20 patients were given postoperative radiotherapy. Regular follow-up was done in outpatient department every month upto three years.

Procedure

This procedure was two surgical teams effort one head and neck team of surgeons started at neck, while other general surgeons (Prof. Khalid Durrani and his team) started at abdomen site. This technique consists of resection of pharynx, larynx and esophagus, pharynx and esophagus was replaced by stomach which was mobilized by abdominal incision and is drawn up through the esophageal bed into the posterior mediastinum and anastomost to the pharynx. A general endotracheal anaestehtist was used. Patient cleaned and toweled from chin above to the suprapubic region below. The operation started by head and neck surgeon team through sorenson's incision, pharynx and larynx were mobilized from carotid sheath on each side. We also removed the thyroid and parathyroid gland of the involved side in the specimen. The trachea divided and tracheostomy created. The general surgical team opened the abdomen through upper paramedian incision. The abdominal esophagus freed followed by mobilization of both curvatures of stomach dividing the left gastric artery but preserving the right gastroepiploic artery. At last first two parts of duedunom was freed and pyloromytomy performed then thoracic esophagus was mobilized by blunt finger dissection from above and below.

Once it was free stomach was pulled into the neck through the posterior medina stinum. The pharynx divided at the level of hyoid, esophagus divided from stomach and this opening was overswen. Now a separate horizantal incision was made in the fundus of the stomach and stitch to the pharynx in two layers. Two radivac drains stitched and closed in customary manner and patient shifted to ICU for first 24 hours.

RESULTS

This study consists of 20 patients with advanced stage of squamous cell carcinomas of hypopharynx. There are 20 patients, 8 male and 12 female (Table 1).

Age range was 30-60 years, one patient was below 30 years, 7 were in between 30-40 while 12 patients were in 41-60 years (Table 2).

Regarding the major risk factors noted in this study, 14 patients (70%) were smoker, 4 patients having habit of pan chewing (20%) and 2 patients had iron deficiency anaemia (10%) (Table 3).

Table 4 shows, anatomical site and size of tumour. The incidence was post-cricoid carcinoma

14 (70%) pyriform fossa 5 (26.66%) and posterior pharyngeal wall tumour 1 (5%).

Regarding nodal involvement, 5 patients had No (25%), 10 patients with N1, and 5 with N2 (Table 5).

Table 1: Sex Distribution

Sex	Number	Percent
Male	8	40
Female	12	60
Total	20	100

Table 2: Age Distribution

Age (Years)	Number	Percent
<30	1	5
31-40	7	35
41-60	12	60

Table 3: Major Risk Factors

Risk factors	Number	Percent
Smoking	14	70
Pan chewing	4	20
Iron deficiency anaemia	2	10

Table 4: Tumour Site and Size distribution

Tumour Size	Post-cricoid	Pyriform fossa	Post-pharyngeal
T1	-	-	-
T2	-	-	-
T3/T4	14	5	1

Table 5: Nodal Metastasis

Nodal metstasis	Number	Percent
N0	5	25
N1	10	50
N2	5	25
N3	-	-

All the 20 patients were treated by laryngopharyngo-oesopharegectomy with stomach pull-up and in 15 patients neck dissection done at the same time and all patients given postoperative radiotherapy (Table 6).

Survival was evaluated after surgery with regular follow-up showing 8 patients (40%), disease free, 6 patients (30%) under observation on follow-up, 4patients (20%) died and 2 patients (1-%) unknown (dead) (Table 7).

Regarding the complications of the procedures, 2 patients (10%) developed with pharyngogastric stenosis, 2 had (10%) recurrence of disease (10%), 4 patients had pneumothorax (20%), while rupture of treachea occurred 1 patient (5%) (Table 8).

Table 6: Site

Site oesophagectomy	Total laryngopharyngo + stomach pull-upblock	TLPO oesophagectomy + neck
Post cricoid	14	11
Pyriform fossa	5	4
Post-pharyngeal wall	1	-

Table 7: Results

Outcome	Number	Percent
Disease free on followup	8	40
Under observation on followup	6	30
Died	4	20
Unknown	2	10

Table 8: Post-operative Complications

Complication	Number	Percent
Pharyngogastric stenosis	2	10
Recurrence of disease	2	10
Pneumothorax	4	20
Rupture of traechea	1	5

DISCUSSION

The squamous cell carcinoma of the hypopharynx is a rare tumour as evidenced by the reports in international literature.[7-14]

Age specific incidence rates for pharyngeal cancer show an increased risk of developing the disease with increasing age for both men and

Fig. 1. Soren-sen U-shaped skin incision.

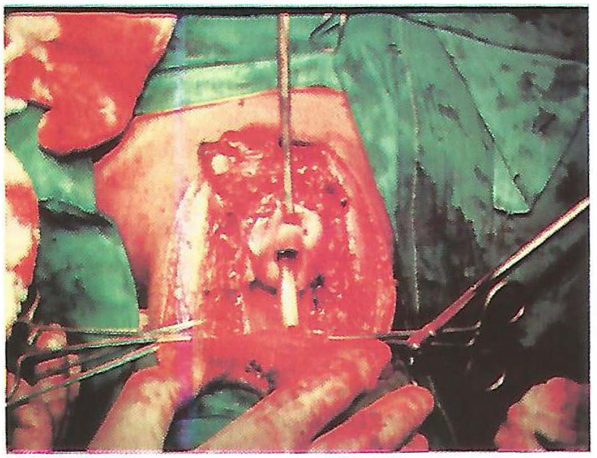

Fig. 2. Exposure of larynx and pharynx.

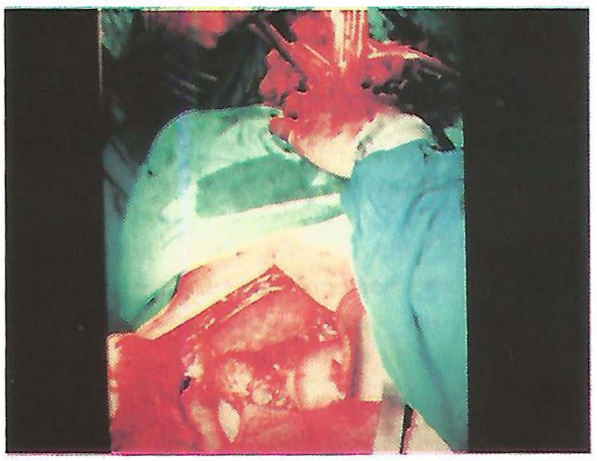

Fig. 3. Laparotomy showing stomach and neck dissection..

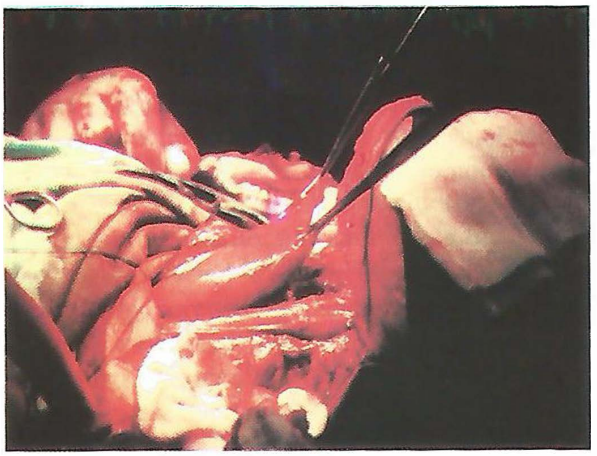

Fig. 4. Stomach pulled into the neck, carotid vessels visible.

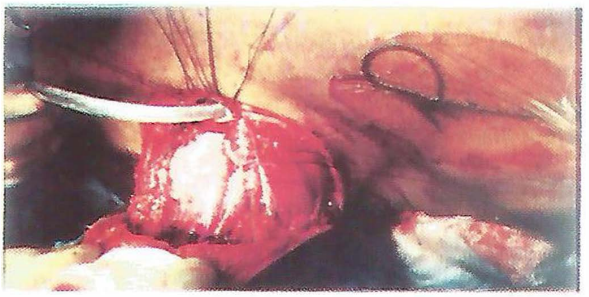

Fig. 5. Neck dissection and tracheostomy.

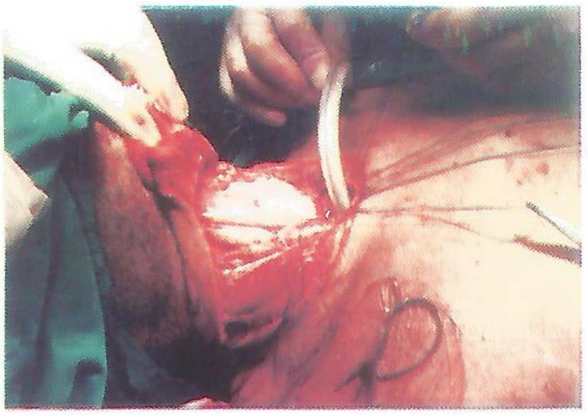

Fig. 6. Neck dissection and tracheostomy.

women. We also noted the SAME observation the age range in between 40-60 years.

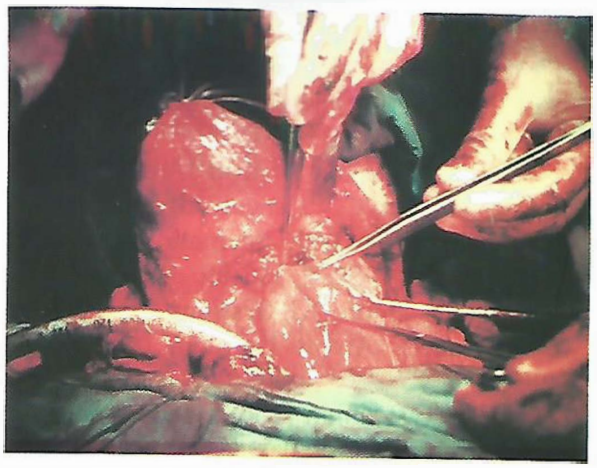

Fig. 7. Operated specimens showing larynx pharynx esophags with tumour.

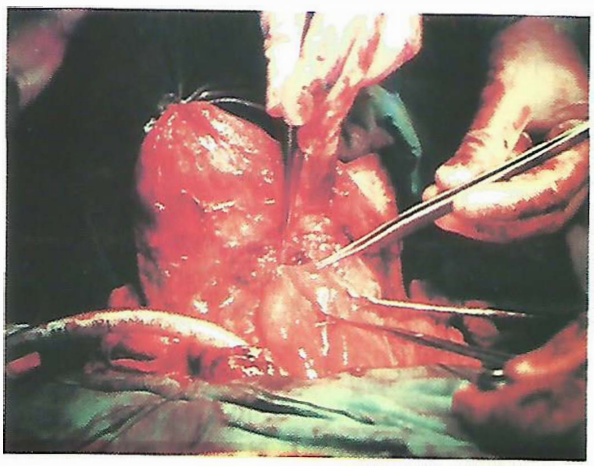

Fig. 8. Anastomosis of stomach to the base of tongue.

Major risk factors evaluated in this study were smoking, pan chewing and iron deficiency anaemia, these are similar to other reports by Larsson et al.[15] Postcricoid carcinoma is most common in female reported firstly in Sweden by Ahlbon[16] and Jacobsson[17].

Treatment options depend upon both the patietn and tumour, which is radiotherapy or surgery or both. The most importat causes of untreatability include advance age, poor general condition, local tumour inoperability and extensive neck disease. Distant metastasis is also a contraindication but are rare at presentation. At T1 and T2 stage radiotherapy is the treatment of choice.[18] Patients who are considered surgically untreatable on the basis that the disease is unrespectable may a considered for radiotherapy with palliative intent. When there is advanced stage carcinoma, T3 and T4, surgery is the first therapeutic option. Total laryngopharyngo-oesophagectomy with stomach pull-up is a procedure of choice for curing the advanced stage of carcinoma of hypopharynx. The procedure offers a significant chance of locoregional control of the disease and early postoperative oral feeding. Reconstruction after surgery depends upon local extent of disease, general condition of the patient and facilities available.[6] The reconstruction possibilities are skin flap, and visceral replacemnt. Skin flaps are pectoralis major myocutaneous flap and radial forearm flap. All skin flaps require tubing before suturing and therefore have a vertical suture line as well as proximal and distal anastomosis. They have high fistula and stenois s rate.[19] Radial forearm flap needs the facility of microvascular surgery which is not freely available everywhere. Th common visceral reconstruciton are, free jejunal transfer, colonic transposition and stomach pull-up. Like radical forearm flap, the free jejunal transfer also requires the facilities of microvascular surgery. Colonic transpossition may only be appropriate for palliation of extensive oesopharyngeal disease. There is more than one anastomosis and the high risk of break and fistula formation. here is also high risk of stricture formation.

Stomach pull-up has certain advantages. The stomach has an excellent blood supply so that local necrosis and fistula are extremely uncommon.[20,21] It allows a single anastomosis that can be as high as the oropharynx. It permits earlier restoration of swallowing and there is minimum chance of stricture formation.

In our study we noted that in 20 patients, having T3 and T4 tumour treated by surgery survival rate is 40% in three years.

Results from different instituions quoted overall 5 years survival figures of approximately 35% for hypopharyngeal tumours treated with surgery. In the Liverpoorl series the 5 years tumours specific survival for hypopharyngeal carcinoma treated by surgery was 28%.[14]

Regarding postoperative comomp-lications in our study, 4 patients (20%0 had pneumothroax, rupture of trachea in 1 patient 5%. In late complication there was pharyngogastric steonosis in

2 patients (10%), and recurrence of disease in 2 patients (10%). In the literature, the complication for this procedure varies from 22% to 100%. The largest series of pharyngolaryngo-oesopharyngeal and gstric transposition had mortality of 9%. In the literature the local recurrence rate varies widely 7.4%, 42%, even 5.4% as compared to our result which 10%.

CONCLUSION

We conclude that total laryngo-oesophagectomy with stomach pull is a procedure of choice for the advanced stage of carcinoma of hypopharynx. The procedure offers a significant chance of locoregional control of the disease and early postoperative oral feeding.

REFERENCES

1. Hoftman HT, Luiky H, Karrell MA, Jatin PS. Hypopharyngeal cancer patient evaluation. Laryngoscopy 1997; 107: 1005-17.
2. Fabian RL, Carcinoma of the larynx and cervical oesophagus. The larynx. A multidiscoiplinary approach. Edited by Marvino P. 1988; p 531-42.
3. Saalch eM, Abdullah Wahab AA, Kamal MM. Age and sex incidence of hypoharyngeal tumours in upper Egypt Assait University Experience JLO 1995; 109:737-40.
4. Harhey BEJ, Bottril IB, Howard DJ. A third deca's experience with the gastric pull-up operation for hypopharyngeal carcinoma; changing patterns of use. JLO 1989; 113: 241-43.
5. Bradley PJ. Survey of current management of laryngeal and hypopharyngeal cancer. J R Col Surg Edinb 1989; 34: 197-200.
6. Ayshford CA, Walsh RM, Watkinson JC. Reconstructive techniques currently used following resection of hypopharyngeal carcinoma. JLO 1999; 113: 145-46.
7. Pere F, Avedian V, Eschwege F, Barret A, Schwaab G, Marandas P, Vanderbrouck C. A retrospective study of 131 cases, carcinoma of the posterior pharyngeal wall. Cancer 1978; 42: 2490-93.
8. McNeill R. Surgical management of carcinoma of the posterior pharyngeal wall head and neck surgery. 1981; 3:389-94.
9. Talton BM, Elkon D, Kim JA, Fitz-Hugh GS, Constable WC. Cancer of the posterior hypopharyngeal wall. International J Pak Oncol Biol Physic 1981; 7: 597-99.
10. Marks JE, smith DG, Sessions DG. Pharyngeal wall cancer. Archiv Laryngol 1985; 111: 79-85.
11. Jaulerry C, Brumin F, Radriguez J, Butaini JP, Brugere J. Carcinomas de la paro, posterieure du pharynx. Expereince de I, Institute Curie, Analyse des resultants de la radiotherapie les Annals d'oto. Laryngo Logie (Paris), 1986; 103:559-63.
12. Techgraeber JF, McConnel Ms. Treatment of posterior pharyngeal wall carcinoma Otolaryngol, head and neck surgery, 1986; 94: 97-200.
13. Spiro RM, Kelly J, Luna Vega A, Tarrison LB, Strong FM. Squamous carcinoma of the posterior pharyngeal wall. Am J Surg 1990; 160: 420-23.
14. Jones AS, Stell PD. Squamous carcinoma of the posterior pharyngeal wall. Clinical Otolaryngol 1991; 16: 462-65.
15. Larsson LG, Standstrom A and Westling D. Relationship of plummer vision disease to cancer of the upper alimentary tract in Seeden. Cancer Research 1975; 35:3308-16.
16. Ahlbom ME. simple achlorhydric anaemia, plummer vinsion syndrome and carcinoma of the mouth, pharnx and oesopharyngus in women. Br Med J 1936; 2:331-33.
17. Jacobsson F. Carcinoma of the hypopharynx. A clinical study of 322 cases, treated at radioumhammet, 1951; 1931-42. Acta Radiolog 35:1-21.
18. Jones AS. The management of early hypopharyngeal cancer primary radiotherapy and salvage surgery. Clin Otolaryngol 1992; 17: 545-49.
19. Maran AGD, Gaze M, Wilson JA. Tumour of hypopharynx, stell and mamens head and neck surg, 3rd edition, 1993; 160-75.

20. Bulman CH. A ten years audit of the management of laryngeal and hypopharyngeal. Can J R Coll Surg Eding 1998; 34: 197-200.
21. Spiro RM, Bairs MS, shah JP, Strong EW. Gastric transposition for head and neck cancer. A critical update. Am J Surg 1991; 162:348-52.

The Authors:

Abdul Hadi,
Professor & Head of Department of ENT
Shaikh Zayed Medical Complex,
Lahore.

Sarfraz Latif
Trainee Registrar
Department of ENT
Shaikh Zayed Medical Complex,
Lahore.

Address for Correspondence:

Abdul Hadi,
Professor & Head of Department of ENT
Shaikh Zayed Medical Complex,
Lahore.