

## Delorme Procedure for Complete Rectal Prolapse In Young Adults –An analysis of 7 Cases

M. Tufail, H.J. Majid, Harun Majid Dar, G. Qasmi, A. Javed, Z. Siddique

Department of General Surgery, Unit-II, Shaikh Zayed Hospital, Lahore

*Entrails don't care for travel, Entrails don't care for stress: Entrails are better kept folded inside you For outside, they make a mess. Connie Bensley 1929: 'Entrails' (1987)*

### ABSTRACT

The problem of full-thickness rectal prolapse is formidable, with no clear predominant treatment of choice. Several operations have been proposed to correct rectal prolapse which can be divided into transabdominal and perineal procedures. Delorme operation is a suitable procedure for elderly and/or medically unfit patients with rectal prolapse. However, good results have also been demonstrated for younger patients, suggesting that the operation may have wider application. From January 2001 to September 2003, 07 young adult patients underwent the Delorme repair of rectal prolapse in our unit with good results. The main outcomes measured were method of anesthesia, morbidity, mortality, recurrence rates, length of follow-up, and incontinence. In the 07 patients, the mean age of the patients was 24 years. The mean operating time was 55 minutes. Four patients were administered general anesthesia and 03 were administered spinal anesthesia. The mean postoperative stay was 05 days. No patients died as a result of the procedure. Patients were followed up for 3 – 33 months. Preoperative incontinence was present in 02 patients, both of whom improved after the procedure. Postoperative incontinence was seen in only one of these patients but that too seemed to improve with time. No recurrent postoperative prolapse has yet been seen. None of the patients had complications that required operative intervention in the postoperative period. Although, the best operation for rectal prolapse remains a controversial subject, we believe that the Delorme Operation offers a promising option for the treatment of rectal prolapse even in young adults.

**Key Words:** Delorme Operation, Rectal Prolapse.

### INTRODUCTION

The problem of full-thickness rectal prolapse is formidable, with no clear predominant treatment of choice. Several operations have been proposed to correct rectal prolapse which can be divided into transabdominal and perineal procedures<sup>1</sup>. Delorme operation is a suitable procedure for elderly and/or medically unfit patients with rectal prolapse<sup>2-4</sup>. However, good results have also been demonstrated for younger patients, suggesting that the operation may have wider application<sup>5</sup>. The principle consists of an extensive perineal excision of the mucosa covering the prolapse, and a longitudinal plication of the rectal

wall<sup>1-7</sup>. From January 2001 to September 2003, 07 young adult patients underwent the Delorme repair of rectal prolapse in our unit with good results.

### PATIENTS AND METHODS

#### Hypothesis

The Delorme operation is a safe, effective, and durable treatment for complete rectal prolapse in young adults.

#### Design

Retrospective analysis of outcomes in young adult patients undergoing the Delorme Operation.

### Setting

Surgical Unit II, Shaikh Zayed Hospital and Federal Post-graduate Medical Institute, Lahore which is a tertiary referral center with a general surgery residency training program.

### Patients

A total of 07 consecutive young adult patients undergoing surgery for the treatment of complete rectal prolapse during the study period (January 2001 – September 2003).

### Intervention

Delorme operation.

### Main outcomes measured

Method of anesthesia, morbidity, mortality, recurrence rates, length of follow-up, and incontinence.

### Operative technique

Delorme operation comprises of stripping of redundant mucosa and plication of the muscle wall to create a ring followed by re-suturing of anal mucosa to rectal mucosa (Figs 1 – 11).

## RESULTS

In the 07 patients, the mean age of the patients was 24 years (range 21 to 32 years) and the mean length of prolapse was 8.2 cm (range 05 – 12 cm). The mean operating time was 55 minutes (range 45 min – 90 min).

Four patients were administered general anesthesia and 03 were administered spinal anesthesia.

No complications related to the type of anaesthesia were noted. No blood transfusions were needed. The mean postoperative stay was 05 days (range 03 to 07 days).

No patients died as a result of the procedure. Patients were followed up for 3 – 33 months. Preoperative incontinence was present in 02 patients, both of whom improved after the procedure. Postoperatively, incontinence was seen in only one of these patients but that too seemed to improve with time. No recurrent postoperative prolapse has yet been seen. None of the patients had complications that required operative intervention in the postoperative period.

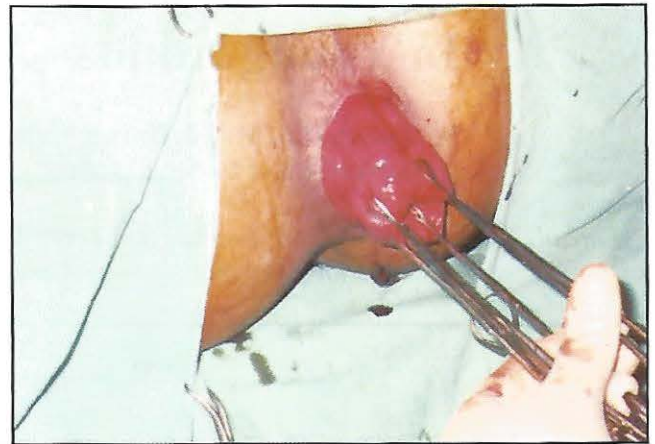

Fig. 1: Displaying the prolapse under G.A.

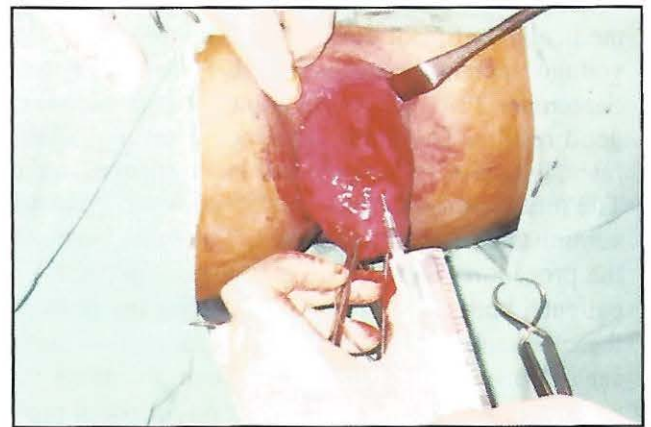

Fig. 2. Extensive sub-mucosal infiltration of Adrenaline solution reduces the bleeding and displays a better plane of dissection.

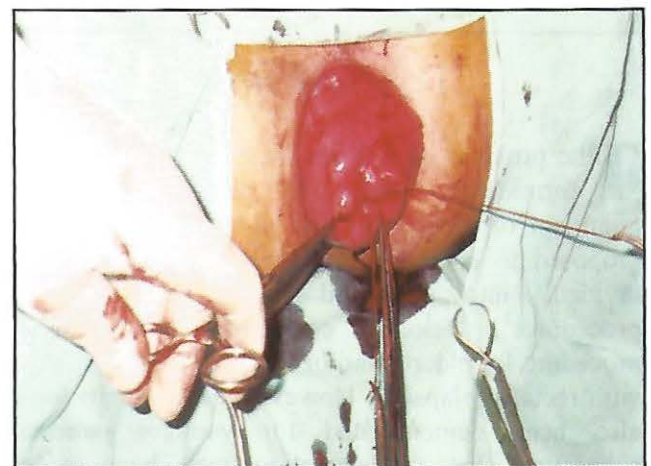
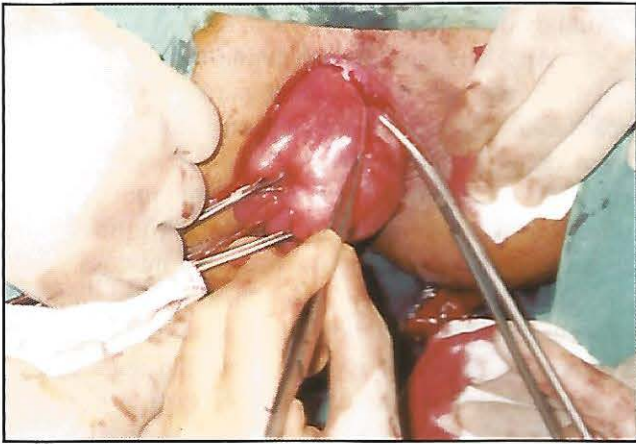


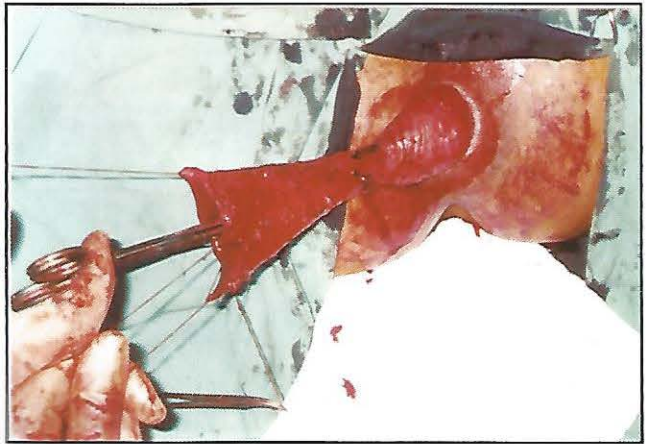
Fig.3. A purse-string stitch at the apex of the prolapse allows better control during surgery and helps demarcate the proximal limit of the mucosal excision.



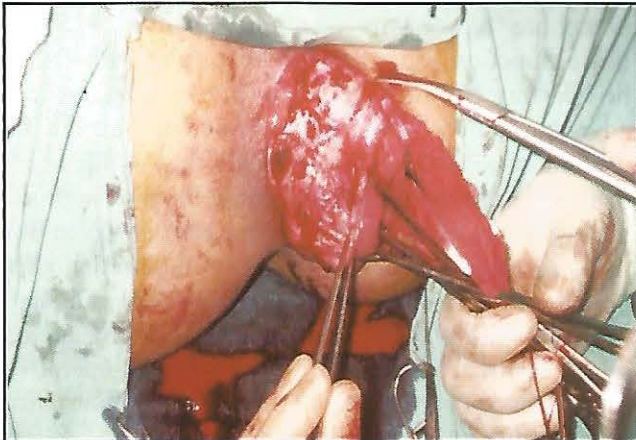
Delorme Procedure for Complete Rectal Prolapse



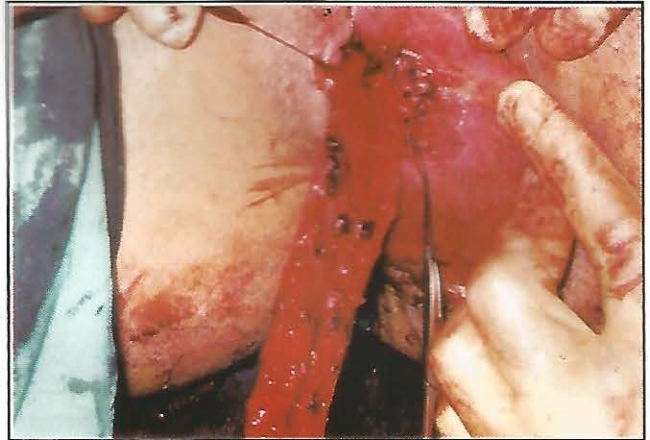**Fig. 4.** Careful dissection of the mucosa off the underlying muscle commences close to the muco-cutaneous junction.



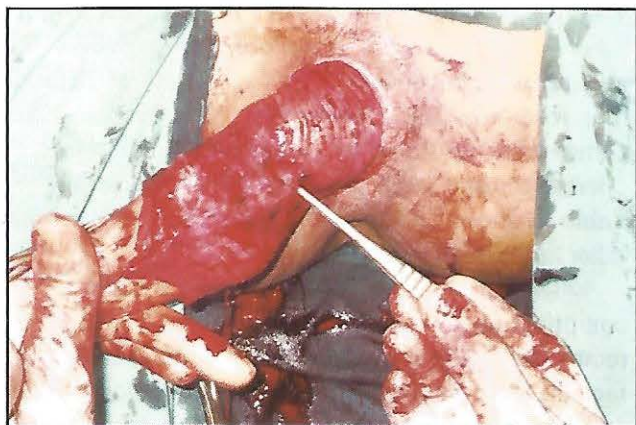
**Fig. 7.** Displaying the "cone" of mucosa.



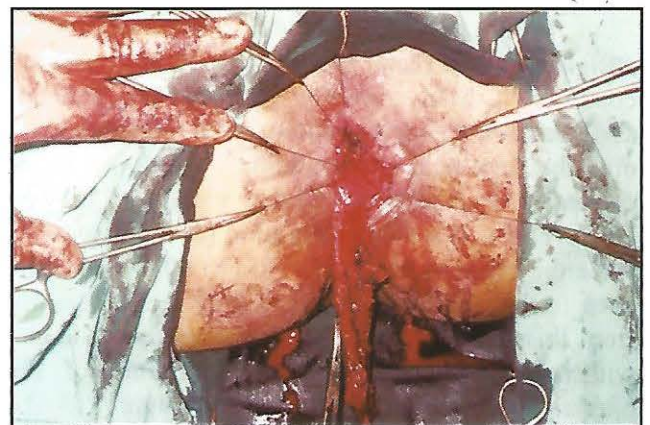
**Fig. 5.** Dissection proceeds circumferentially and proximally with careful preservation of underlying muscle.



**Fig. 8.** Simultaneous excision of the mucosa and plication-reduction of the muscle.



**Fig. 6:** Meticulous hemostasis.



**Fig. 9.** Mucosal excision and muscle placcation proceeds circumferentially.



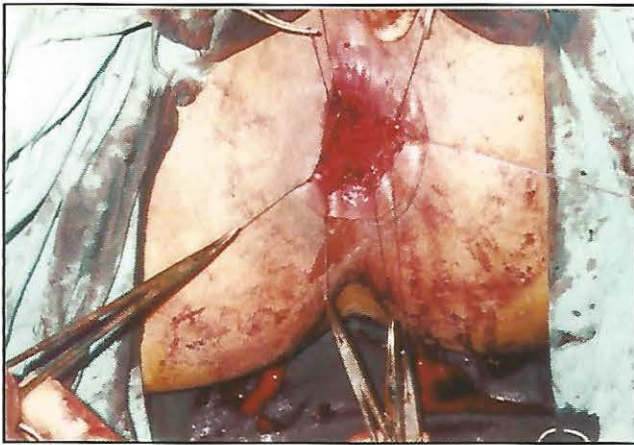


Fig. 10. Mucosal excision and muscle placement complete..

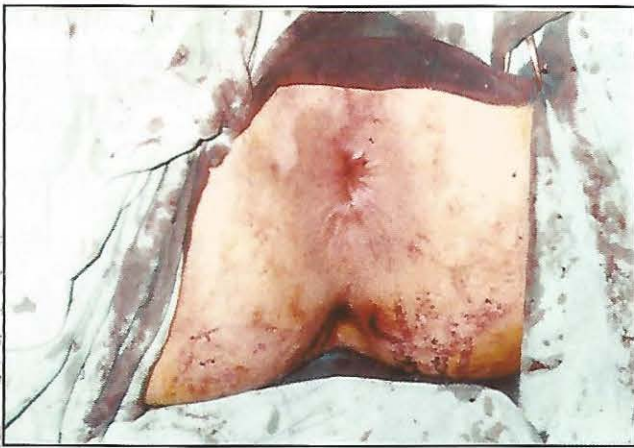

Fig.11. Plicated muscle reduced.

## DISCUSSION

There have been over a 100 operations designed to treat rectal prolapse which is a disabling condition<sup>8,9</sup>. Many involve opening the patient's abdomen and fixing the rectum from the inside with or without the help of a synthetic mesh or prosthesis or entail a resection of the redundant bowel. However this is a major operation for many patients since they tend to be in their 70's to 80's, with some even in their nineties, and they may recover poorly from this. Even if the patient was younger and can withstand such a procedure, the nature of the operation is such that the nerve supply to the bladder and sexual organs may become damaged. Such patients may therefore be able to get rid of their rectal prolapse, but end up with bladder or

sexual dysfunction<sup>1-9</sup>.

An alternative to the abdominal procedure is the Delorme operation - first performed over 100 years ago by a French surgeon on soldiers suffering from rectal prolapse due to infective dysentery! It consists of stripping of redundant mucosa and plication of musculature to form a ring followed by re-suturing of anal mucosa to rectal mucosa. This operation is generally safer than an abdominal procedure as it does not involve cutting open the abdomen<sup>10</sup>. All of it is done from the anus and is better tolerated by the elderly. Senapati et al report that although abdominal rectopexy is safe and has a low recurrence rate (< 5 percent), it involves the hazards of a laparotomy. In addition, up to 40 percent of patients become constipated after rectopexy which may be debilitating. Delorme procedure has a low morbidity, results in good bowel function, and has a low recurrence rate. It can be performed on unfit patients with possible advantages over rectopexy and perhaps should be used more readily<sup>10</sup>. Unfortunately the Achilles heel of this procedure is that, according to some authors, the rectal prolapse tends to come back in up to 30-40% of patients, who then may require another operation<sup>1-11</sup>. However, we have obtained promising initial results with this procedure in young adults with minimal complications, no post-operative incontinence or constipation and no recurrence noted as yet.

Although many authors have sporadically reported the procedure in young adults, no previous study has dealt with it exclusively in this age group. Most previous authors have described the procedure suitable for old age patients or for patients who were otherwise considered unsuitable or high-risk for abdominal procedures<sup>12-16</sup>. Comparative data is therefore lacking. However, our results are comparable to those of other authors in terms of operative time and duration of hospital stay<sup>1-13</sup>. Table 1 shows a review of the results of various other authors.

In our small series we did not see any of the complications, post-operative incontinence or recurrence of prolapse. This may be attributed to the fact that our number of patients was much smaller and all our patients were younger and otherwise fit with no significant co-morbidities. In most of the



## Delorme Procedure for Complete Rectal Prolapse

**Table 1. Comparative Data**

Author	Total Patients	Complications	Incontinence	Recurrence	Mortality
Watkins et al <sup>2</sup> 2003	52	4%	15.3%	6% at 2 yrs 10% at 5 yrs	Nil
Muller-Lobeck et al <sup>17</sup> 1996	72	15.1%	4.1%	-	Nil
Tobin & Scott <sup>5</sup> 1994	43	-	46%	25%	-
Oliver et al <sup>18</sup> 1994	41	25%	-	22%	01 patient
Johnson et al <sup>19</sup> 1993	25	24%	Reduced post-operatively	32%	Nil
Abulafi et al <sup>20</sup> 1992	22	-	13.6%	4.5%	nil

other series, either the majority of patients belonged to a much older age group with potential comorbidities or had various underlying factors predisposing to a higher complication rate, post-operative incontinence or recurrence of the prolapse. Muller-Lobeck et al<sup>17</sup> in their large series have reported a total complication-rate of 15.1%, bleeding (2.9%), suture line disruption (7.3%), abscesses (1.5%) and stenosis (1%). Oliver et al<sup>18</sup> have observed that pitfalls in performing this procedure relate primarily to associated perineal and colonic conditions. They have considered weak or absent sphincter tone, perineal descent, and previous sphincter injury as most prominent among these conditions. They have also noted that extensive diverticular disease may prohibit effective and complete proximal mucosectomy. An inadequate mucosectomy sets the stage for early recurrence of prolapse.

Numerous surgical procedures have been suggested to treat rectal prolapse in young adults. In elderly and high-risk patients, perineal approaches such as Delorme procedure and perineal rectosigmoidectomy (Altemeier's procedure) have been preferred, although the incidence of recurrence and the rate of persistent incontinence seem to be high when compared with transabdominal procedures. Functional results of transabdominal procedures, including mesh or suture rectopexy and resection-rectopexy, are thought to be associated with low recurrence rates and improved continence. Transabdominal procedures, however, usually imply rectal mobilization and fixation, colonic resection, or both, and some concern is voiced that morbidity, in terms of infection or leakage, and mortality could be increased. If we focus on surgical outcome, our own as yet limited experience of the Delorme

operation for rectal prolapse in young adults shows that this approach is safe and effective, and functional results with respect to recurrence are favorable. However, the controversy "which operation is appropriate?" cannot be answered definitely as yet, as a clear definition of rectal prolapse, the extent of a standardized diagnostic assessment, and the type of surgical procedure have not been identified in published series. Randomized trials are needed to improve the evidence with which the optimal surgical treatment of rectal prolapse can be defined.

## CONCLUSIONS

Although, the best operation for rectal prolapse remains a controversial subject, we believe that the Delorme Operation offers a promising option for the treatment of rectal prolapse even in young adults. The Delorme operation is a safe and effective surgical treatment for complete rectal prolapse. The risk of recurrent prolapse is low, the procedure may be safely performed in patients with significant medical comorbidities, the procedure may be repeated for recurrence and is free of all the risks associated with the pelvic dissection of an abdominal procedure especially in young adult males.

## REFERENCES

1. Wu JS, Fazio VW. Surgical intervention for adult patients with rectal prolapse. *Curr Gastroenterol Rep.* 2003; 5: 425-30.
2. Watkins BP, Landercasper J, Belzer GE, Rechner P, Knudson R, Bintz M, Lambert P. Long-term follow-up of the modified

- Delorme procedure for rectal prolapse. *Arch Surg.* 2003; 138: 498-502.
3. Chiu HH, Chen JB, Wang HM, Tsai CY, Chao TH. Surgical treatment for rectal prolapse. *Zhonghua Yi Xue Za Zhi (Taipei).* 2001; 64: 95-100
4. Kling KM, Rongione AJ, Evans B, McFadden DW. The Delorme procedure: a useful operation for complicated rectal prolapse in the elderly. *Am Surg.* 1997; 63: 845.
5. Tobin SA, Scott IH. Delorme operation for rectal prolapse. *Br J Surg.* 1994; 81: 1681-4.
6. Cosendey BA, Chapuis G. Status of the Delorme operation in surgery of rectal prolapse. *Helv Chir Acta.* 1990; 56: 943-6.
7. Palma F. Benignancy of the Delorme operation in the treatment of rectal prolapse. Indications and results. *Rev Esp Enferm Apar Dig.* 1989;76 (6 Pt 1):585-8.
8. Lindsey I, Cunningham C. Surgical treatment of rectal prolapse. *Br J Surg.* 2004; 91: 1389.
9. Schiedeck TH, Schwandner O, Scheele J, Farke S, Bruch HP. Rectal prolapse: which surgical option is appropriate? *Langenbecks Arch Surg.* 2004 Mar 5.
10. Senapati A, Nicholls RJ, Thomson JP, Phillips RK. Results of Delorme procedure for rectal prolapse. *Dis Colon Rectum.* 1994; 37: 456-60.
11. Lazorthes F, Liagre A, Iovino F. Rectal prolapse. *J Chir (Paris).* 2000; 137: 76-81.
12. Martinez Hernandez-Magro P, Villanueva Saenz E, Sandoval Munro RD. Surgical treatment of complete rectal prolapse. Experience at a colon and rectal surgery service. *Rev Gastroenterol Mex.* 2003; 68: 185-91.
13. Ayav A, Bresler L, Brunaud L, Zarnegar R, Boissel P. Surgical management of combined rectal and genital prolapse in young patients: transabdominal approach. *Int J Colorectal Dis.* 2004 Oct 13.
14. Bachoo P, Brazzelli M, Grant A. Surgery for complete rectal prolapse in adults. *Cochrane Database Syst Rev.* 2000(2):CD001758.
15. Ribault L, Gournier JP. Total rectal prolapse in young adults. Apropos of 10 cases in Africans. *J Chir (Paris).* 1988; 125(12):730-2.
16. Aluwihare AP. Rectal prolapse in young adults. *Ann Acad Med Singapore.* 1987; 16: 527-8.
17. Muller-Lobeck H, Duschka L, Schleifer P, Henne T. Rehn-Delorme operation in pelvic floor insufficiency. *Zentralbl Chir.* 1996; 121: 692-7.
18. Oliver GC, Vachon D, Eisenstat TE, Rubin RJ, Salvati EP. Delorme procedure for complete rectal prolapse in severely debilitated patients. An analysis of 41 cases. *Dis Colon Rectum.* 1994; 37: 461-7.
19. Johnson E, Nygaard K, Bakka A. Rectal prolapse. Experiences with rectopexy and Delorme operation. *Tidsskr Nor Laegeforen.* 1993; 113: 2693-5.
20. Abulafi AM, Sherman IW, Fiddian RV, Rothwell-Jackson RL. Delorme operation for rectal prolapse. *Ann R Coll Surg Engl.* 1990 Nov; 72(6): 382-5. Comment in: *Ann R Coll Surg Engl.* 1992; 74: 150.

#### The Authors:

Muhammad Tufail  
Professor and Head of  
Department of Surgery-II  
Shaikh Zayed Medical Complex  
Lahore

Haroon Javaid Majid  
Assistant Professor  
Department of Surgery  
Shaikh Zayed Medical Complex  
Lahore

Harun Majid Dar  
Assistant Professor  
Department of Surgery  
Shaikh Zayed Medical Complex  
Lahore.