

Photogrammetric Analysis: An Adjunct To Cephalometric Analysis

Raheela Yasmeen and Ayyaz Ali Khan

Department of Oral Health Sciences, Shaikh Zayed Federal Postgraduate Medical Institute, Lahore.

INTRODUCTION

All medical specialties interested in improving facial appearance need to measure the face to quantify the desired facial changes¹. Patient aesthetic expectations and smile enhancement can be achieved through the use of facial analysis. This process allows each member of the restorative team (i.e., clinician, specialist, dental technician) to diagnose the patient and develop a comprehensive treatment plan for his or her specific needs. Treatment planning according to facial architecture and dental configuration allows function and harmonious aesthetics to be improved.

The introduction of radiographic cephalometrics in 1934 by Hofrath in Germany and Broadbent in America provided both a research and a clinical tool for the study of malocclusion and underlying skeletal disproportions. Cephalometric measurement of the face in terms of aesthetics can be difficult and misleading due to the variability of the intra-cranial reference lines². Extra-cranial references can be more accurate, but can be time-consuming to apply.

A proportional analysis system has been proposed for the soft tissue facial profile in the natural head position³. The analysis of the soft tissue facial profile from photographic records provides information on the morphology of the profile and its relationship with the underlying dentoskeletal tissues¹.

The present article attempts to demonstrate that photogrammetric analysis is a predictable means to evaluate the components of an attractive face for use as a guide during aesthetic dental treatment⁴.

PHOTOGRAMMETRIC ANALYSIS

For the analysis of the relationship between the craniofacial skeleton and the soft-tissue facial

contours, profile and frontal photographs are taken under standardized conditions.

Patient positioning

This is done with the patient sitting upright in habitual occlusion and with relaxed lips and mentalis muscles. A precondition for obtaining comparable photographs, which can be evaluated by measurement, is a reproducible position of the patient. Such profile and frontal photographic views can be achieved in various ways:

1. The frontal and lateral views are taken with a single camera as described by Simon, with the patient in two different positions;
2. The two photographs are taken with a single camera, obtaining the different aspects by the use of mirrors (A.M. Schwarz).
3. The frontal and lateral views are taken simultaneously, using two cameras (Dassch-Neumann, 1987).

Profile view

For the profile exposure the camera is placed parallel to the facial midsagittal with the Frankfurt horizontal plane. The patient's eyes should be looking straight ahead, unstrained, and the ears should be uncovered... A.M. Schwarz (1958) compiled a detailed classification of the variations of the facial profile. The evaluation is based upon the construction of three reference planes;

1. Eye-ear plane (Frankfurt horizontal plane);
2. Skin nasion perpendicular, according to Dreyfuss;
3. Orbital perpendicular, according to Simon.

The perpendiculars delimit the "jaws-profile field" (JPF). In children this is 13-14 mm wide, in adults 15-17 mm.

In an ideal average-value face the subnasal

point touches the skin nasion perpendicular. The "Soft-tissue chin point" (the most ventral point of the soft-tissue part of the chin) lies in the center of the "Jaw-Profile field," the "Skin gnathion" (the most inferior chin point) lies on the orbital perpendicular. Depending on the location of the subnasal point relative to the skin nasion perpendicular, there are typical profile variations; (Fig. 1).

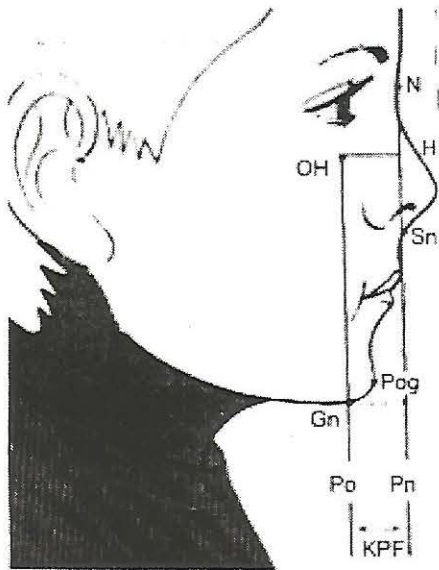


Fig. 1: Typical profile variations.

- Average face=Subnasale lying on the skin nasion perpendicular; anteface=Subnasale lying in front of the skin nasion perpendicular.
- Ante face = Subnasale lying in front of the skin nasion perpendicular
- Retro face = Subnasale lying behind the skin nasion perpendicular.

In straight-jawed ante- and retro faces the chin is displaced to the same extent as the subnasale point. For each of the above profiles two further facial types can be differentiated, depending on the changed location of the "soft-tissue pogonion" relative to the subnasale. There are forward-slanting or backward-slanting faces, that means nine different types of profile in all (Fig. 2).

The mouth profile is of great importance for facial expression. The contours of the lower face

are, therefore further analyzed by means of the mouth tangent. This method of profile analysis has the disadvantage of being affected by a high or low – positioned cartilaginous tragus, and its clinical significance is thereby reduced. The analysis can also be performed on the lateral cephalogram which is preferable as it allows to use the bony landmarks of the external auditory meatus. The clinical value of the photographic picture is that it is more realistic and gives a better record of any changes in the soft-tissue profile during the course of treatment, which is of great advantage.

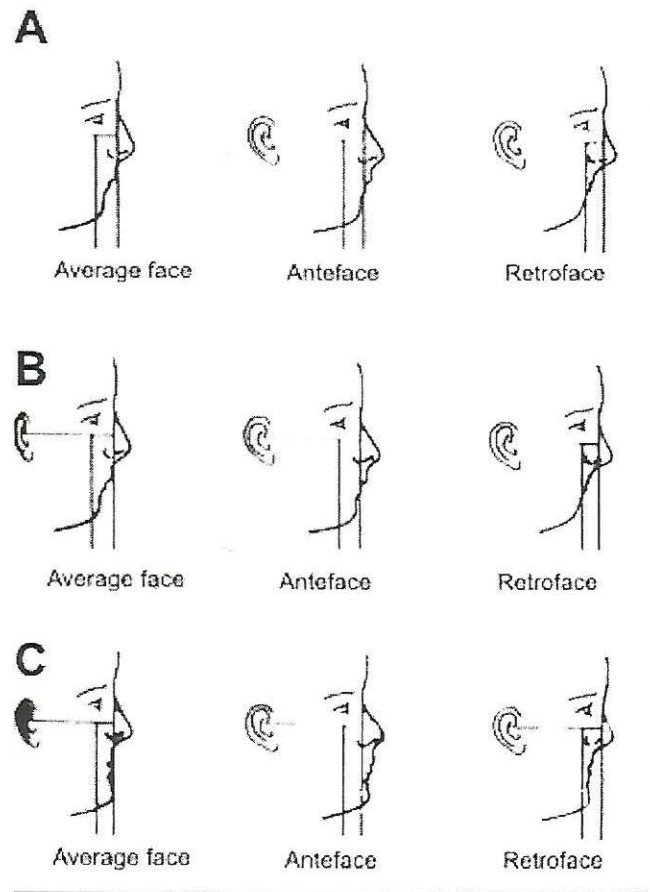


Fig. 2: A, Straight jawed profile; B, Backward slanting profile; C, Forward slanting profile.

Facial Divergence

Another analysis of the lateral photograph is based upon evaluation of the divergence of the face. The inclination between the following two reference lines is here analyzed.

1. The line joining the forehead and the border of the upper lip
2. The line joining the border of the upper lip and soft-tissue pogonion.

The following three profile types are differentiated according to the relationship between these two lines;

- Straight :The two lines form a nearly straight line.
- Convex profile: The two reference lines from an angle indicating a relative backward displacement of the chin (posterior divergent).
- Concave profile: The two reference lines from an angle indicating a relative forward displacement of the chin (anterior Divergent) (Fig. 3)

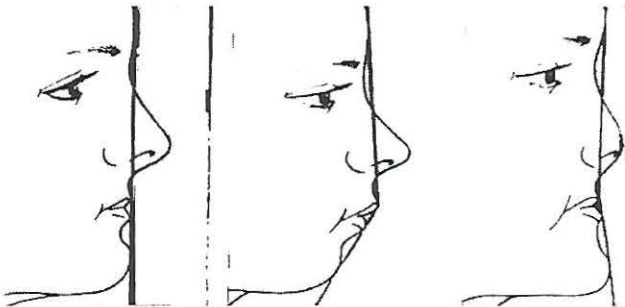

Fig. 3: Left Average. Center Convex. Right concave profiles.

Frontal view

Analysis of the frontal picture is assessing major disproportions and asymmetries of the face in transverse and vertical planes. Even a slight rotation the head from the plane of the film can result in major discrepancies between the relative patterns of the right left facial contours. It is, therefore, absolutely essential for the camera to be placed perpendicular to the facial midline during the exposure.

For clinical analysis it has proven practical to mark the two orbital points and to construct the skin nasion perpendicular. During the evaluation of the diagnostician should bear in mind that a mild degree of physiologic asymmetry between the two

sides of the face exists in nearly all normal individuals (Fig. 4.)

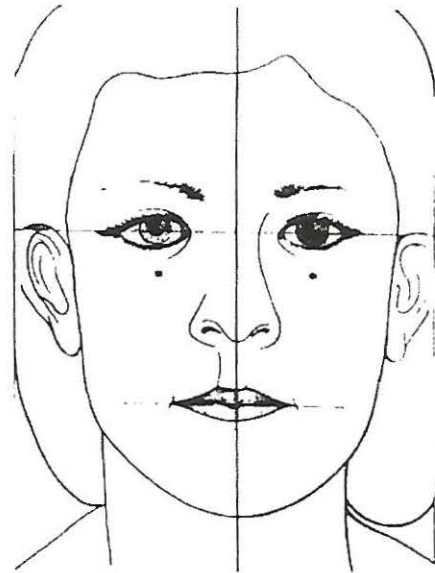


Fig. 4: Facial symmetry

Vertical reference plane = Facial mid sagittal plane. (Joins the skin nasion point to the Subnasal point). Upper horizontal plane Bipupillary line. Lower horizontal plane = Parallel to the bipupuillary line through stomion.

DISCUSSION

Facial soft-tissue size and shape are influenced by age and sex, and to a minor extent by skeletal class⁵ Facial landmark identifications and analysis is useful to describe normal soft tissue growth and development of the human face through volume changes and to assess the presence of sexual dimorphism.: From 6 yr of age to adulthood, facial soft tissues increased their volumes by >40%, with different growth patterns in boys and girls⁶

The photogrammetric analysis can also be applied to see ethnic differences in facial proportions among different races⁷. It can also be used to analyze the soft tissue changes following orthodontic treatment in patients treated with either an extraction or a nonextraction treatment modality⁸. It has been observed that, the nasolabial angle became significantly more obtuse among the

female subjects who were treated with four first premolar extractions and that, after treatment the upper and lower lips are retracted significantly more in the extraction group compared with the nonextraction group⁷

Recommendations

This simple method of profile analysis may provide aesthetic surgeons with a simple formula and reference data for creation and application of an attractive face.

More research specifically testing the photogrammetric method in a clinical setting is needed. The overall process of evaluating facial changes from photographs is both technique and operator sensitive.

This straightforward method can provide a simple tool for profile analysis and treatment planning designed to create an attractive face.

REFERENCES

1. Fernandez-Riveiro P, Smyth-Chamosa E, Suarez-Quintanilla D, Suarez-Cunqueiro M. Angular photogrammetric analysis of the soft tissue facial profile. *Eur J Orthod*, 2003; 25(4): 393-9.
2. Bass NM. Measurement of the profile angle and the aesthetic analysis of the facial profile. *Journal of Orthodontics* 2003; 30: 3-9.
3. Kishi S. Characteristics of proportional analysis for soft tissue facial profile: epidemiological possibilities of measurement item reduction. *J Oral Sci*. 1999; 41: 111-5.
4. Rifkin R. Facial analysis: a comprehensive approach to treatment planning in aesthetic dentistry. *Pract Periodontics Aesthet Dent*. 2000; 12: 865-71.
5. Ferrario VF, Sforza C. Size and shape of soft-tissue facial profile: effects of age, gender, and skeletal class. *Cleft Palate Craniofac J* 1997; 34: 498-504.
6. Ferrario VF, Sforza C, Poggio CE, Schmitz JH. Facial volume changes during normal human growth and development. *Anat Rec*. 1998; 250: 480-87.
7. Lundstrom A, Cooke MS. Proportional analysis of the facial profile in natural head position in Caucasian and Chinese children. *Br J Orthod*. 1991; 18:43-9.
8. Cummins DM, Bishara SE, Jakobsen JR. A computer assisted photogrammetric analysis of soft tissue changes after orthodontic treatment. Part II: Results. *Am J Orthod Dentofacial Orthop*, 1995;108: 38-47

The Authors:

Raheela Yasmeen
Department of Oral Health Sciences,
Shaikh Zayed Postgraduate Medical Institute,
Hospital,
Lahore.

Ayyaz Ali Khan
Assistant Professor
Department of Oral Health Sciences,
Shaikh Zayed Postgraduate Medical Institute,
Lahore.

Address for Correspondence:

Ayyaz Ali Khan
Assistant Professor
Department of Oral Health Sciences,
Shaikh Zayed Postgraduate Medical Institute,
Lahore.