

# Fixation of Thoracolumbar Fractures by Fixator Internae

Shafique Ahmed Shafaq, Abbas Bajwa and Zaigham Ali  
Department of Orthopaedics, Shaikh Zayed Hospital, Lahore

## ABSTRACT

Study included 20 patients with instable burst fractures presented in Accident and Emergency Department, Shaikh Zayed Hospital, Lahore. Twelve patients were male and eight patients were female. Age ranges from 15 to 29 years. Ten patients were without neurological loss, five were partial neurological involvement and 5 were complete neurological cases. All these patients were operated and stabilized with posterior interpedicular system called fixator internae developed by AO. This instruments allows stable fixation limited only two adjacent spinal segments. With fixator internae it is possible to add distraction or compression to the involved segments. It is able to reduce effectively the middle column by ligamentotaxis. All patients in this series had a minimum follow up of one year. Most patients in this series had a near anatomical reduction of all three columns in the involved segments. It was also possible to re-established the normal Lordosis of the lumbar spine. AO International Classification of thoracolumbar fractures were followed. 10 patients without neurological loss were mobile after 2 weeks. Five patients with partial neurological loss recovered fully and 3 patients complete neurological loss, one patient recovered partially and but 2 patients remained paraplegic and bed ridden. Results were satisfactory and cost effective.

## INTRODUCTION

With modern high speed vehicular trauma and falls from heights are associated with thoracolumbar spine injuries. One person in 20,000 sustain a spinal cord injury each year 14,000 Americans suffer spinal cord injury each year .8 to 10 thousand are left paralyzed. Motorcycle accidents are associated with multiple level injuries of spine. Thoracolumbar spine injuries occur frequently in male patient between 15 and 29 years. Approximately 90% of all spinal fractures occur in thoracic and lumbar spine. Various forces act on spine in traumatic situations including axial loading, flexion, extension, shear forces ,axial rotation and compressive forces result in wedge and burst fractures.Dennis<sup>19</sup> developed the three column concept which is important for the understanding of spinal stability. Generally speaking thoracolumbar fractures behave in an unstable manner if middle column<sup>2</sup> is disrupted and sign of middle column disruption is widening of interpedicular distance on AP view radiographs .Quantification of sagittal plane

alignment can be performed using the COBB<sup>20</sup> method in lateral view radiographs. MRI has become an important tool in assessing the integrity of PLC. The most important determinant of recovery is the magnitude of initial neurological deficit. Time to surgery and residual bone in canal has minor effects in recovery .Sensory recovery usually precedes motor recovery for incomplete paraplegia.

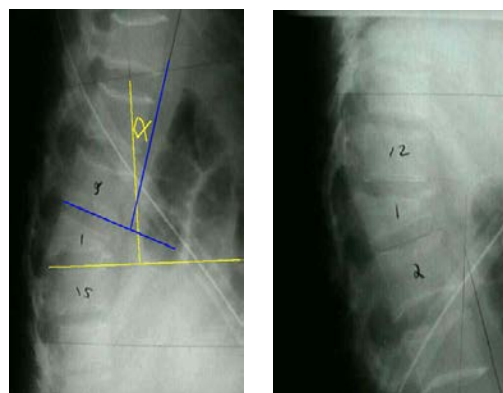


Fig. 1: Measurement of angle by COBB method.

### AIMS AND OBJECTIVES

- 1) Aim is to save the patient from the long period of incapacity with conservative treatment.
- 2) To save the patient from permanent neurological deficit.
- 3) Surgical intervention and stabilization of spine helps in early mobilization of the patient.

### MATERIALS AND METHODS

AO spinal internal fixation system includes:

- 1) 5 mm transpedicular schanz<sup>6</sup> screws
- 2) 7mm fully threaded stainless steel rods
- 3) Screws are self tapping ,standard size is 35 mm of threaded length .

This system allows axial,angular and rotational adjustability and permits segmental fixation of injured spinal segment .

### THORACOLUMBAR FIXATION BY FIXATOR INTERNAE




Fig. 2: Fixator interna.

Where spinal cord was involved, the neurological level was determined. Presence of an incomplete or complete neurological injury was determined. Detailed initial neurological examination including sensory, motor and reflex function was carried out. Presence of sacral motor sparing indicates good prognosis for motor function recovery.

If spine is sufficiently unstable we offer early surgery and our aim is to provide anatomical alignment with stable fixation .indirect decompression of canal can be accomplished by restoration of anatomical alignment, distraction across the vertebral body and hyperlordosis of the injured lumbar segment .Fixator interna achieve these goals.

Posterior approach to thoracolumbar spine made through a standard midline longitudinal exposure with reflection of erector spinae muscle laterally to the tips of transverse processes.

Location for screw insertion was determined through the respective facet joint space and middle of transverse process are the most important reference point opening was made in pedicle with a drill and a self tapping screw is passed through the pedicle into vertebral body. The whole procedure was carried out under image intensifier .

Thoracolumbar fractures needing surgical fixation includes : spine fractures causing partial or complete neurological deficit.

Fractures affecting mechanical stability:

- 1) Wedging of vertebral body >50%
- 2) Kyphosis >20%
- 3) Decrease in spinal canal diameter>50%
- 4) Disruptive compromise of posterior column.

Frankel<sup>10</sup> grading system was used both pre and post operatively to grade the functional deficit of the patients.

Methods of recording the functional deficit after spinal cord injury

- |         |  |
|---------|--|
| Grade A | Complete no sensory or motor function is preserved below the level of lesion |
| Grade B | Incomplete: sensation present motor power absent                             |
| Grade C | Incomplete: sensations present motor power present (nonfunctional)           |
| Grade D | Incomplete: sensations present motor   |

Grade E power present (functional grade 4 or 5)  
Complete recovery: normal motor and sensory function

## RESULTS

Twenty patients with unstable burst fractures of thoracolumbar vertebrae with neurological deficit were fixed with fixator internae in the department of Orthopedics at Shaikh Zayed Hospital Lahore in 3 years period. Out of 20 patients 8 were female (40%) and 12 were male (60%). All the patients had unstable burst fractures (100%). Mode of injury was RTA in 10 patients (50%), Fall from height in 6 patients (30%) and Trauma in 4 patients (20%).

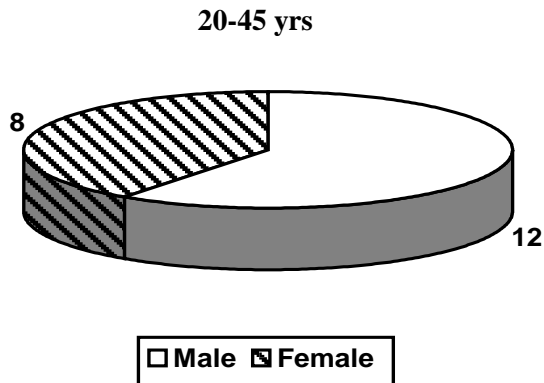


Fig. 3: Gender distribution.

AO international classification<sup>6</sup> of thoracolumbar fractures was followed. A 3 and B 2 type of fractures were included in this study.

- 1) Patients were admitted from accident and emergency department:
- 2) Common causes of injury turned out to be motor vehicle accidents and fall from the height
- 3) Head injury was ruled out
- 4) Chest, abdomen and extremities were examined for occult injuries
- 5) Spinal shock was ruled out.

The final position was checked on image intensifier.

Results after fixation were assessed by

Frankel Grading System<sup>5</sup> which is as follows:

Grade	Pre-operative patients		Post-operative patients	
	No.	%	No.	%
E	10	50%	13	65%
D	3	15%	2	10%
C	3	15%	2	10%
B	2	10%	1	5%
A	2	10%	2	10%
Ambulatory without support 17 patients				85%
Ambulatory with support 1 patients				5%
Unable to walk (para pelagic) 2 patients				10%

Patients were encouraged to sit and do exercises of lower extremity

Average stay in hospital was 11 days

Average time for walking with support was 15 days postoperatively.

Patients were reviewed both clinically and radiologically after every 2 weeks for 1 year .

In the present series all patients were able to sit with support 24 hrs after surgery .Wheel chair mobilization was started 48-72 hrs after surgery, which simplified the nursing care and facilitated early rehabilitation in our patients .

## CASES

### Case 1:

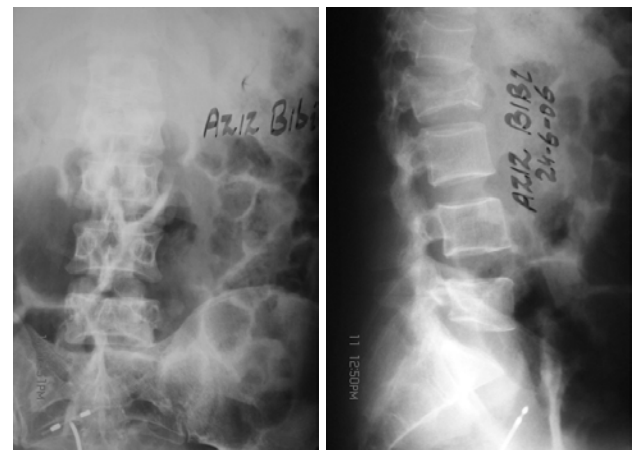


Fig. 4: Burst fracture of L2.

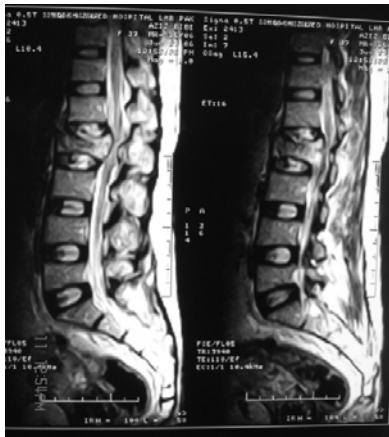

Fig. 5: MRI shows burst fracture L2 with retropulsed vertebral body fragments comprising thecal sac.

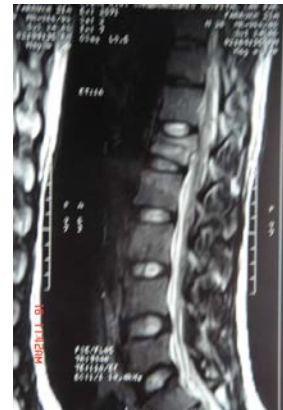

Fig. 8: Burst fracture L1 with retropulsion of vertebral body impinging on thecal sac.

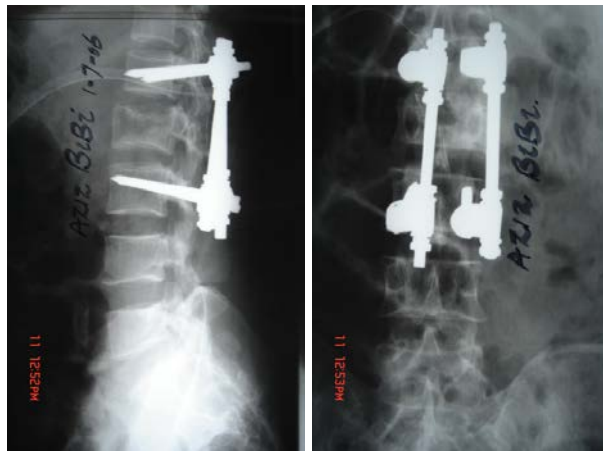

Fig. 6: Post operative x-rays after fixation.

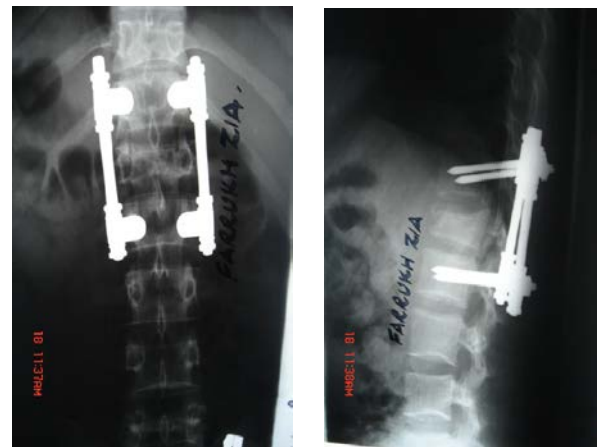


Fig. 9: Post operative x-rays after fixation.

## CASE 2

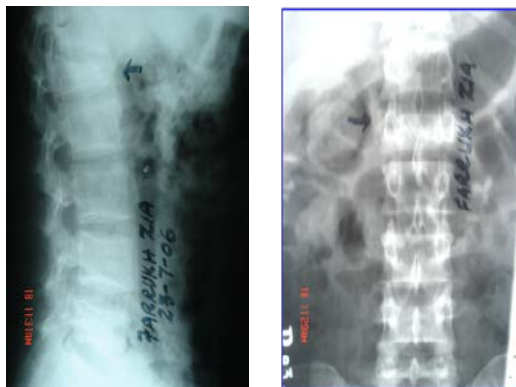


Fig. 7: Burst fracture of L1.

## COMPLICATIONS:

1)	Injury to great vessels	0
2)	DVT	0
3)	Sup. wound infection	1(10%)
4)	Deep infection	0
5)	Hardware failure	1(10%)

## DISCUSSION

Burst fractures treated conservatively implies a long period of incapacity (6 months), with large impact to patients daily and productive life, also taking into consideration the psychological effect created by six or more months of treatment due to a spinal fracture.

If spine is sufficiently unstable we offer early surgery and our aim is to provide anatomical alignment with stable fixation .Indirect decompression of the canal can be accomplished by restoration of anatomical alignment, distraction across the vertebral body by hyperlordosis of the injured lumbar segment. Fixator internae achieve these goals by ligamentotaxis.

This decompression of spinal canal is effective in thoracolumbar junction and lumbar spine .Recovery is better in early posterior instrumentation. 15 patients (75%) were able to walk without support after 4 weeks. 3 patients (15%) had stable spine but motor function regained after three months and they were ambulatory with support after three months. 2 patients (10%) remained paraplegic and bed ridden. Nursing care improved in these patients with stable fixation and they were mobile only on wheel chairs.

AO system allows axial, angular and rotational adjustability and permits segmental fixation of injured spinal segments .

It is effective in obtaining decompression of spinal canal in burst fractures and also limiting instrumentation to only two spinal motion segments.

We propose surgical treatment of thoracolumbar burst fracture with neurological involvement by fixator internae. It has good results and is cost effective.

## REFERENCES

1. Dick W. The fixator interne" as a versatile implant for supne surgery. *Spine* 1987; 12:882.
2. Convery FR, Minter MA, Smith RW, Emerson SM. Fracture-dislocation of the dorsolumbar spine. Acute operative stabilization by Harrington instrumentation. *Spine* 1978; 3:160-66.
3. Dickson JH, Harrington PR, Erwin WD 1978 Results of reduction and stabilization of the severely fractured thoracic and lumbar spine. *J Bone Joint Surg* 1978; 60A:799-805
4. Flesh JR, Leider LL, Erickson DL, Chou, SN, Bradford DS. Harrington instrumentation and spine fusion for unstable fractures and fracture-dislocations of the thoracic and lumbar spine. *J Bone Joint Surg* 1977; 59A: 143-153.
5. Frankel HL, Hancock DO, Hyslop G, Melzak J, Michaelis LS, Ungar GH, Vernon JDS, Walsh JJ The value of postural reduction in the initial management of closed injuries of the spine with paraplegia and tetraplegia. *Paraplegia* 1969; 7:179-92.
6. Gertzbein SD, Macmichael D, Tile M. Harrington instrumentation as a method of fixation in fractures of the spine. A critical analysis of deficiencies. *J Bone Joint Surg* 1982; 64B:526-29.
7. Hasday CA, Passoff TL, Perry J. Gate abnormalities arising from iatrogenic loss of lumbar lordosis secondary to Harrington instrumentation in lumbar fractures. *Spine* 1983; 8:501-11.
8. Holm ST, Nachemson A. Nutritional changes in the canine intervertebral disc after spinal fusion. *Clinical Orthopaedics* 1982; 169:243-58.
9. Jacobs RR, Dahners LE, Gertzbein S, Nordwall A, Mathys, R. A locking hook—spinal rod: current status of development. *Paraplegia* 1983; 21:197-207
10. Jacobs RR, Nordwall A, Nachemson AL. Reduction, stability, and strength provided by internal fixation systems for thoracolumbar spinal injuries. *Clinical Orthopaedics* 1982; 171:300-8.
11. Osebold WR, Weinstein SL, Sprague BL. Thoracolumbar spine fractures: results of treatment. *Spine* 1981; 6: 13-34
12. Purcell GA, Markolf KL, Dawson EG. Twelfth thoracic—first lumbar vertebral mechanical stability of fractures after Harrington rod instrumentation. *J Bone Joint Surg* 1981; 63A:71-78
13. Stauffer ES, Neil JL. Biomechanical analysis of structural stability of internal fixation in fractures of the thoracolumbar spine. *Clinical Orthopaedics* 1975; 112:159-164
14. Gertzbein SD, Court-Brown CM, Marks P, et al. The neurological outcome following surgery for spinal fractures, *Spine* 1988; 13:641
15. Broom MJ, Jacobs RR. Update 1988: Current

- status of internal fixation of thoracolumbar fractures, J Orthop Trauma 1989; 3:148.
16. Bedbrook GM. Spinal injuries with tetraplegia and paraplegia. J Bone Joint Surg 1979; 61B:267–284
  17. Esses SI. The AO spinal internal fixator. Spine 1989; 14:373.
  18. Jacobs RR, Nordwall A, Nachemson A. Reduction, stability and strength provided by internal fixation systems for the thoracolumbar spinal injuries. Clin Orthop 1984; 189: 168.
  19. McAfee PC, Yuan HA, Lasada NA. The unstable burst fracture. Spine 1982; 7:365.
  20. Osebold WR, Weinstein SL, Sprague, BL. Thoracolumbar spine fractures: results of treatment. Spine, 1981; 6:13.

**The Authors:**

Shafique Ahmed Shafaq  
Profesor  
Department of Orthopaedics,  
Shaikh Zayed Hospital  
Lahore

Abbas Bajwa,  
Assistant Professor  
Department of Orthopaedic,  
Shaikh Zayed Hospital,  
Lahore

Zaigham Ali  
Trainee registrar  
Shaikh Zayed Hospital,  
Lahore.

**Address for Correspondence:**

Abbas bajwa  
88 G Block, Model Town  
Lahore  
03004190983