Proceeding S.Z.P.G.M.I. Vol: 30(2): pp. 103-110, 2016

Bilio-Vascular Anatomy of Pakistani Population, Living Donor Liver Transplant

Amer Latif[1], Tariq Ali Bangash[1], Sumbul Naz[2], Faisal Naseer[2], Arshad Kamal Butt3

[1] *Hepato-Biliary Pancreatic Liver Transplant Unit Shaikh Zayed Medical Complex, Lahore*
[2]*Department of Surgery Dow University of Health Sciences, Karachi*
[3]*Department of Gastroenterology-Hepatology Shaikh Zayed Medical Complex, Lahore*

ABSTRACT

Introduction: Vascular and Biliary complications remain the Achilles' heels of right-lobe Living Donor Liver Transplantation (LDLT) and contribute significantly to the postoperative morbidity and mortality, therefore precise understanding of the anatomical landmarks and common variations is step towards safe LDLT. **Methodology:** Retrospective data was collected for the first 110 LDLT patients, their pre-operative investigations to delineate the liver anatomy (C.T Scan for arterial, portal and hepatic venous anatomy and MRCP for biliary anatomy) along with operative report and operative cholangiogram were evaluated and recorded. **Results:** Portal vein: 98(89.1%) had classic anatomy; 10(9.1%) had type 2 and two patients (1.8%) were found to have type 3 anatomic variation. Hepatic artery: 89 (80.9%) patients had type 1 conventional anatomy, rest of the patients 21 (19.09%) had variable anatomy. Biliary tree: 82 (74.5%) had normal anatomy, type 2 in 15(13.6%), type 3a in 5(4.5%), type 3b in 5(4.5%) and type 4b in 3 (2.7%) patients whereas none of the donors had type 4a anatomy. Hepatic vein: 83.6% of the patients had non-type 1a anatomy, resulting in at least one significant segment 5 or 8 or short hepatic vein to be reconstructed. **Conclusion:** Anatomic variability is the rule rather than the exception in liver surgery and understanding anatomic variations of the right lobe is key in successful living donor liver transplantation. The frequency of bilio-vascular anatomic variations in LDLT Pakistani population is no different from other parts of world.

Key words: Living donor liver transplant, anatomic variations, and Pakistani population.

INTRODUCTION

Living donor liver transplantation is the main stay of liver transplantation in countries where availability of the cadaveric liver is not possible due to religious and social beliefs[1,2]. It is technically more demanding and challenging than cadaveric whole liver transplantation since the outcome of donor and recipient is dependent on the surgery. Donor liver hepatectomy should be performed in such a way that a well vascularized and adequate graft is harvested for the recipient without disturbing the anatomy of the remaining liver as well as sufficient volume of liver is left behind for the donor[3,4,5]. Thus, great attention should be given to the anatomy of hepatic artery, portal vein, hepatic vein, and biliary tract.

Vascular and Biliary complications remain the Achilles' heels of right-lobe living donor liver transplantation[6], and contribute significantly to the postoperative morbidity and mortality, and are occasionally the causes of graft loss[7], so extra care is needed in harvesting the graft as the life of donor and recipient is dependent on graft of donor. Precise understanding of the

anatomical landmarks and common variations is step towards safe LDLT[8,9].

Since the vascular and biliary anatomy of liver is difficult and inconsistent so extensive workup and researches have been done to delineate the surgical anatomy of living donors and came up with different variants with different frequencies in their population[10,11] but none of the research has documented it in south eastern population. The donor anatomical variations we have encountered are described in detail in this article. The aim of this study is to determine the frequency of vasculo-biliary anatomic variations of living liver donors for the Pakistani population.

METHODOLOGY

Sheikh Zaid hospital performed their first transplant on august 13, 2011, till now 110 transplants have been carried out. We retrospectively collected the data of all patients who underwent liver transplantation in our hospital from 2011 to May, 2017. We retrospectively reviewed the donors' preoperative radiologic imaging and intraoperative surgical findings to assess the surgical liver anatomy.

All donors undergoing liver transplant were included in the study, their pre-operative investigations to delineate the liver anatomy (C.T Scan for arterial, portal and hepatic venous anatomy and MRCP for biliary anatomy) along with operative report and operative cholangiogram were evaluated and recorded. Anatomy of the portal veins and hepatic arteries, biliary ducts and portal veins were classified as follows[12]

Portal venous anatomy

Portal vein (PV) variations were classified in three different anatomic patterns (Fig. 1).

Type 1 (common type): The right portal vein originates from the main portal vein, divides in right anterior and right posterior portal branches within the RL.

Type 2 (trifurcation type): The right PV is absent and both right anterior PV and right posterior PV arise directly from the main PV.

Type 3 (left type): The right PV is absent and the right anterior PV arises directly from the left branch of the PV

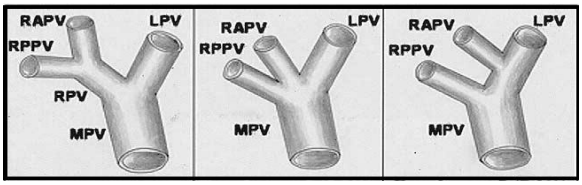

Figure 1 Classification of the portal vein anatomy. LPV, left portal vein; MPV, main portal vein; RAPV, right anterior portal vein; RPPV, right posterior portal vein; RPV, right portal vein.

Hepatic Arterial anatomy

Anatomic variations of the hepatic artery (HA) were classified into five types (Fig. 2).

Type 1: The common hepatic artery arises from the celiac axis, after a common section divides into the gastroduodenal artery and proper hepatic artery. The proper HA runs into the hilum and at a variable length divides into left and right hepatic arteries, which supply arterial blood to corresponding hemi livers. Then the right HA runs to the right hemi liver and divides into right anterior and right posterior branches.

Type 2: The left HA arises directly from the left gastric artery; it can be an accessory vessel, when it is present in addition to a normal left HA (type 2a), or a complete replacement vessel, when it represents the unique arterial supply to the left liver (type 2b).

Type 3: The right HA arises directly from the superior mesenteric artery (SMA), as an accessory artery, when present in addition to a normal right HA (type 3a), or as a complete replacement, when it represents the unique arterial supply to the right liver (type 3b).

Type 4: Presence of a double accessory (type 4a) or double replacement (type 4b); the left HA arises from the left gastric artery and the right HA arises from the SMA.

Type 5: The common HA arises from the SMA.

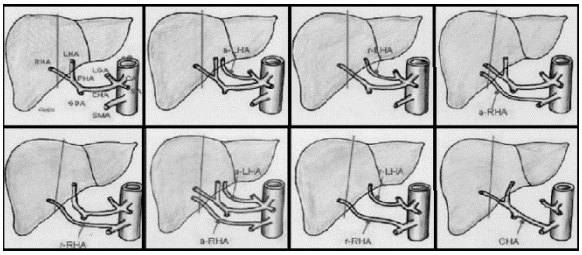

Figure 2 Classification of the hepatic artery anatomy. AO, aorta; CA, celiac axis; CHA, common hepatic artery; GDA, gastroduodenal artery; LGA, left gastric artery; LHA, left hepatic artery; PHA, proper hepatic artery; RHA, right hepatic artery; SA, splenic artery; SMA, superior mesenteric artery.

Biliary anatomy

Anatomic variations of the biliary tract were classified into four types (Fig. 3).

Type 1: Right anterior and right posterior hepatic ducts (HD) join together to form the right HD.

Type 2: The right HD is absent and the right anterior HD and right posterior HD join directly to the confluence with the left HD to form the common HD.

Type 3: The right anterior HD (type 3a) or the right posterior HD (type 3b) opens directly into the left HD.

Type 4: The right anterior HD (type 4a) or the right posterior HD (type 4b) opens directly into the common HD.

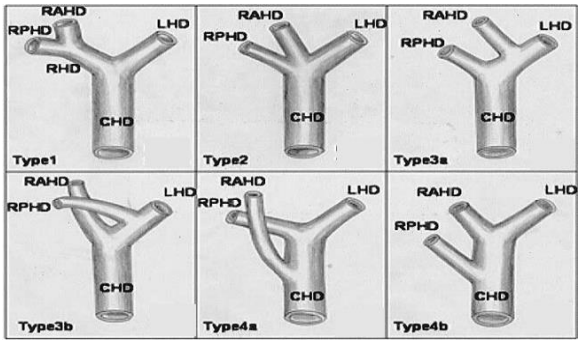

Figure 3 Classification of the biliary tree anatomy. CHD, common hepatic duct; LHD, left hepatic duct; RAHD, right anterior hepatic duct; RPHD, right posterior hepatic duct.

Hepatic vein anatomy

Based on the presence or absence of significant segment 5 and 8 accessory hepatic veins (S5 and S8) and one or more accessory short hepatic veins (SHV), which needed reconstruction, we proposed four anatomic patterns (Fig. 4).

Type 1: Absence of S5 and S8; absence of SHV (type 1a), or presence of SHV (type 1b).

Type 2: Presence of S5; absence of SHV (type 2a), or presence of SHV (type 2b).

Type 3: Presence of S8; absence of SHV (type 3a), or presence of SHV (type 3b).

Type 4: Presence of both S5 and S8; absence of SHV (type 4a), or presence of SHV (type 4b).

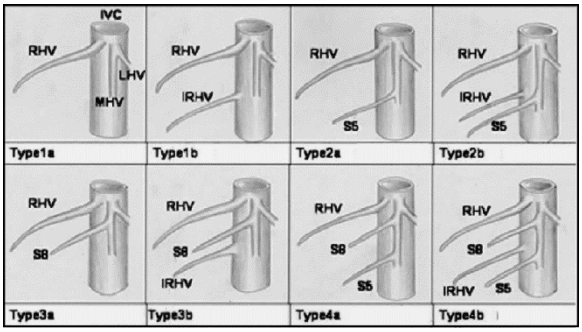

Figure 4 Classification and incidence of the right liver hepatic venous anatomy. IRHV; inferior right hepatic vein; IVC, inferior vena cava; LHV, left hepatic vein; MHV, middle hepatic vein; RHV, right hepatic vein.

RESULTS

Portal venous anatomy

Total of 110 patients underwent right lobe donor hepatectomy, assessment of portal vein anatomy showed that 98(89.1%) patients had type 1 portal anatomy with a single lumen, type 2 anatomy in 10(9.1%) patients and type 3 anatomy in 2(1.8%) patients. All patients had single anastomosis with main portal vein of the recipient by performing the veinoplasty in type2 and type 3 anatomy.

Hepatic Arterial anatomy

Arterial anatomy of the donors showed that 89 (80.9%) patients had type 1 conventional anatomy, rest of the patients 21 (19.09%) had variable anatomy with type 2a in 7(6.4%), type

2b in 2 (1.8%), type 3b in 9(8.2%) type 4b in 2(1.8%), and type 5 in 1(0.9%) patients, whereas no patients had type 3a or 4a arterial anatomy with dual blood supply to right lobe graft.

Biliary anatomy

Biliary anatomy of 110 patients assessed by pre-operative MRCP followed by per-operative cholangiogram and found type 1 biliary anatomy in 82 (74.5%), type 2 in 15(13.6%), type 3a in 5(4.5%), type 3b in 5(4.5%) and type 4b in 3 (2.7%) patients whereas none of the donors had type 4a anatomy (table 1).

Hepatic vein anatomy

Hepatic venous anatomy was classified according to the branches of middle hepatic vein and inferior hepatic veins draining the right lobe of liver with significant flow which needed reconstruction. Variations with frequencies are shown in table 2.

DISCUSSION

The understanding and description of segmental liver anatomy is a cornerstone of hepatobiliary surgery[13,14]. With this understanding, surgeons were able to perform anatomic resections and whole liver transplantation, and then to develop such new and challenging techniques as split liver and living donor transplantation. These procedures require meticulous anatomic assessment in order to avoid graft injury and ensure a safe hepatectomy.

Living liver donation has a surgical risk with donor mortality and morbidity rates of 0.1-1% and 15-25%, respectively. A living donor is a normal individual who is mentally, physically and psychologically healthy. Subjecting a healthy individual to high risk surgery has always been a matter of debate in LDLT which can be balanced with the benefit of recipient and proper selection of donor to avoid any unintended situation. One of the main steps to make LDLT safe for donor is the pre-operative workup and per-operative cholangiogram so that the anatomy can be understood properly and variations in the anatomy can be addressed . To understand and make this procedure further safe we have reported the anatomic finding and variations in our 110 donors. We have simply classified the anatomy of portal vein, hepatic artery, bile duct and hepatic vein, the classification was based on previous articles and literature[14,16-23]

In our experience portal vein anatomy was quite consistent (type 1= 89%) with very few variations, which was also reported in other articles (83.5 to 86.4%) [14,24]. In all our LDLT donors with any type of portal anatomy we performed a single anastomosis with recipient's portal vein, in type 2 and type 3 anatomy venoplasty was done for single anastomosis. Grafts with double portal orifices can be managed with separate anastomoses to the recipient's right and left portal veins, joined together to make one orifice, or connected to a Y-shaped vascular graft at the back table for a single anastomosis in the recipient[25,26,27]. A type 4 portal vein anatomy is also reported by other authors in which the main portal trunk is undivided it enters the liver, gives the right sectorial branches, and then ends in the left liver, crossing the umbilical fissure[28.29]. This type of anatomy was not found in our series but should be considered to be a contraindication to right liver donation.

Many authors have reported extremely variable incidences of hepatic artery pattern[16,17,18,19]; type 1 anatomy incidence ranging from 55% to 76% of patients (table 2), in our experience the frequency of type 1 anatomy (80.7%) was a bit higher than others. During donor hepatectomy, the right HA is identified in the hilar plate and exposed only to the right of the bile duct to avoid devascularization of the biliary tree and a possible segment 4 artery originating from the right HA have to be identified and preserved, maintaining the line of transection distally[30,31]. Right HAs or common HAs originating from SMAs (types 3, 4, 5) usually have good length and caliber and can be quite easily isolated. We anastomosed donor right artery with right artery 87 patients (79.09%), left artery 17 patients (15.45%) or common hepatic artery 6 patients (5.45%) of the recipients.

In our experience we did not encounter any donor with dual blood supply to the right lobe graft i.e. (type 3a or type 4a) anatomy and had single arterial anastomosis in all of our recipients. None of the patients had post-operative hepatic artery thrombosis. All arterial anastomosis was done with 8/0 Prolene in interrupted fashion.

Biliary tree anatomic variations are common as compared to portal vein and hepatic artery consistent with the findings of our experience. Reported Type 1 biliary anatomy incidence is 53% and 72%14,23,24, , . In our study type 1 biliary incidence was 74.5% and Non type 1 biliary incidence was 25.5% and always resulted in two or more biliary ducts. Whereas, type 1 anatomy with very short right hepatic duct also lands in two ducts, this was found in 7 (6.3%) of our patients.

Seventy four patients had single duct after parenchymal transection, rest of the patients had two or more ducts. 74 patients had single ductal anastomosis in recipient, 26 patients had two/three ductal anastomosis and 10 patients had ductoplasty after which they again had single anastomosis. In 2(1.8%) of our patients with type 2 biliary anatomy, while cutting the confluence there is more than 50% circumferential loss of the confluence of left side, as a result these donors had hepaticojejunostomy.

Since non-type 1 biliary anatomy is common so it should not be considered a contraindication to donation but requires accurate pre- and intraoperative radiologic and surgical evaluations in order to plan a careful reconstruction [24,25,34].

Table 1 Anatomic variation of biliary ducts

Type of biliary anatomy	Frequency(%)
1	82(74.5)
2	15(13.6)
3a	05(4.5)
3b	05(4.5)
4a	0(0)
4b	03(2.7)

Table 2 hepatic venous anatomy with variations

Type	Frequency (%)
1a	18(16.4%)
1b	5(4.5%)
2a	8(7.3%)
2b	11(10%)
3a	8(7.3%)
3b	14(12.7%)
4a	37(34.5%)
4b	8(7.3%)

In our transplant center, the RL graft is usually harvested without the middle hepatic vein in order to minimize surgical risk for the donor. But the main middle hepatic vein tributaries (S5 and S8) are preserved and reconstructed to avoid the risk of congestion and graft dysfunction. Hepatic venous anatomy is classified on the basis of reconstruction of segment 5, 8 and inferior hepatic veins.

83.6% of the donors had non type 1a anatomy, resulting in at least one significant segment 5 or 8 or short hepatic vein to be reconstructed during the transplant surgery. 21 (19.09%) patients had one, 62 (56.3%) patients had two and 8 (7.3%) patients had three venous reconstructions which drained into left hepatic vein or vena cava of the recipient. For reconstruction portal venous grafts from explanted liver, umbilical venous grafts and PTFE grafts were used. There was a single patient in which middle hepatic vein was harvested with the graft.

In our study only 11(10%) patients had classic anatomy, whereas rest of the patients had some variations either in portal vein, hepatic artery, biliary tree or hepatic veins which shows that liver anatomy is quite variable and variations are unavoidable. But the incidence of variations in our population is a bit different from previously reported articles so we recommend that anatomic variations should be particularly studied in large group of Pakistani population

Table 3 Reported Anatomic Variations of the Hepatic Artery

Anatomic variation	Our series (n=110)	Hiatt[17] (n = 1,000)	Gruttadauria[18] (n = 701)	Soin[19] (n = 527)	Michels[16] (n = 200)
Type 1 %	80.9	75.7	57.8	69.0	55.0
Type 2 %	8.2	9.7	11.5	14.3	18.0
Type 3 %	8.2	10.6	15.0	8.3	18.0
Type 4 %	1.8	2.3	7.4	1.0	4.0
Type 5 %	0.9	1.5	0.9	2.3	2.5
Others %	0.0	0.2	7.4	6.0	0.5

CONCLUSION

Anatomic variability is the rule rather than the exception in liver surgery and understanding anatomic variations of the right lobe is fundamental in adult to adult living donor liver transplantation. The frequency of bilio-vascular anatomic variations in LDLT Pakistani population is no different from other parts of world. While anatomic variations in the LDLT donor were common, no contraindication to RL harvesting was noted in this study.

REFERENCES

1. Lo CM, Fan ST, Liu CL, et al. Adult-to-adult living liver transplantation using extended right lobe grafts. Ann Surg. 1997;226:261–270. [PMC free article] [PubMed]
2. Kawasaki S, Makuuchi M, Matsunami H, et al. Living related liver transplantation in adults. Ann Surg. 1998;227:269–274. [PMC free article] [PubMed]
3. Makuuchi M, Kawasaki S, Noguchi T, Hashikura Y, Matsunami H, Hayashi K, Harada H, Kakazu T, Takayama T, Kawarasaki H (1993) Donor hepatectomy for living related partial liver transplantation. Surgery 113:395–402.
4. Marcos A (2000) Right lobe living donor liver transplantation: a review. Liver Transplantation 6:3–20.
5. Kawasaki S, Makuuchi M, Miyagawa S, Matsunami H, Hashikura Y, Ikegami T, Kakazu T, Hayashi K, Takayama T, Kawarazaki H (1996) Extended lateral segmentectomy using intraoperative ultrasound to obtain a partial liver graft. Am J Surg 171:286–288.
6. Calne RY. A new technique for biliary drainage in orthotopic liver transplantation utilizing the gall bladder as a pedicle graft conduit between the donor and recipient common bile ducts. Ann Surg 1976; 184: 605–609.
7. Ishiko T, Egawa H, Kasahara M, Nakamura T, Oike F, Kaihara S, et al. Duct-to-duct biliary reconstruction in living donor liver transplantation utilizing right lobe graft. Ann Surg 2002; 236: 235–240.
8. Cheng YF, Chen CL, Huang TL, Chen TY, Lee TY, Chen YS, et al. Single imaging modality evaluation of living donors in liver transplantation: magnetic resonance imaging. Transplantation 2001; 72: 1527–1533.
9. Schroeder T, Malago M, Debatin JF, Testa G, Nadalin S, Broelsch CE, Ruehm SG. Multidetector computed tomographic cholangiography in the evaluation of potential living liver donors. Transplantation 2002; 73: 1972–1973.
10. Imamura H, Makuuchi M, Sakamoto Y, et al. Anatomical keys and pitfalls in living liver transplantation. J Hepatobiliary Pancreat Surg. 2000;7:380–394. [PubMed]
11. Renz JF, Reichert PR, Emond JC. Biliary anatomy as applied to pediatric living donor and split-liver transplantation. Liver Transpl. 2000;6:801–804. [PubMed]
12. Varotti G1, Gondolesi GE, Goldman J,et al. Anatomic variations in right liver living donors. J Am Coll Surg. 2004 Apr;198(4):577-82.

13. The Terminology Committee of the IHPBA. The Brisbane 2000 terminology of hepatic anatomy and resections. HPB Surg 2000;2:333–339.
14. Couinaud C. Controlled hepatectomies and exposure of the intrahepatic bile ducts. Anatomical and technical study. Paris:CCouinaud; 1981.
15. Hwang S. Lee SG, et al. lessons learnt from 1000 living donor liver transplantations in a single center: How to make live donations safe. Liver trsnspl 2006;12:920-27
16. Michels NA. Newer anatomy of the liver and its variant blood supply and collateral circulation.AmJ Surg 1966;112:337–347.
17. Hiatt RJ, Gabbay J, Busuttil RW. Surgical anatomy of the hepatic arteries in 1000 cases. Ann Surg 1994;220:50–52.
18. Gruttadauria S, Scotti Foglieni C, Doria C, et al. The hepatic artery in liver transplantation and surgery: vascular anomalies in 701 cases. Clin Transplant 2001;15:359–363.
19. Soin AS, Friend PJ, Rasmussen A, et al.Donor arterial variations in liver transplantation: management and outcome of 527 consecutives grafts. Br J Surg 1996;83:637–641.
20. Makisalo H, Chaib E, Krokos N, Calne SR. Hepatic arterial variations and liver related diseases of 100 consecutive donors. Transpl Int 1993;6:325–329.
21. Suzuki T, Nakayasu A, Kawabe K, et al. Surgical significance of anatomic variations of hepatic artery. Am J Surg 1971;122:505–512.
22. Hardy KJ, Jones RM. Hepatic artery anatomy in relation to reconstruction in liver transplantation: some unusual variations. Aust NZ J Surg 1994;64:437–440.
23. Kawarada Y, Das BC, Taoka H. Anatomy of the hepatic hilar area: the plate system. J Hepatobiliary Pancreat Surg 2000;7:580–586.
24. Varotti G, Gondolesi GE, Goldman J et al. Anatomic variations in right liver living donors. J Am Coll Surg. 2004 Apr;198(4):577-82.
25. Miller CM, Gondolesi GE, Florman S, et al. One hundred nine living donor liver transplants in adults and children: a singlecenter experience. Ann Surg 2001;234:301–311.
26. Marcos A, Orloff M, Mieles L, et al. Reconstruction of double hepatic arterial and portal venous branches for right-lobe living donor liver transplantation. Liver Transpl 2001;7:673–679.
27. Thayer WP, Claridge JA, Pelletier SJ, et al. Portal vein reconstruction in right lobe living-donor liver transplantation. J Am Coll Surg 2002;194:96–98.
28. Nakamura T, Tanaka K, Kiuchi T, et al. Anatomical variations and surgical strategies in right lobe living donor liver transplantation:lessons from 120 cases. Transplantation 2002;73:1896–1903.
29. Deshpande RR, Heaton ND, Rela M Surgical anatomy of segmental liver transplantation. Br J Surg 2002;89:1078–1088.
30. Marcos A, Harn JM, Fisher RA, et al. Surgical management of anatomical variations of the right lobe in living donor liver transplantation.Ann Surg 2000;231:824–831
31. Renz JF, Reichert PR, Emond JC. Hepatic arterial anatomy as applied to living-donor and split-liver transplantation. Liver Transpl 2000;6:367–369.
32. Kida H, Uchimura M,Okamoto K. Intrahepatic architecture of bile and portal vein. [in Japanese] Tai to sui. 1987;8:1–7.
33. Healey JE, Schroy PC. Anatomy of the biliary ducts within the human liver. Arch Surg 1953;66:599–616.
34. Varotti G,Gondolesi G,Munoz L, et al. Biliary complications in 96 right lobe living donor liver transplants. J Gastrointest Surg 2003;7:271

The Authors

Amir Latif
Hepato-Biliary Pancreatic Liver Transplant Unit
Shaikh Zayed Medical Complex, Lahore

Tariq Ali Bangash
Hepato-Biliary Pancreatic Liver Transplant Unit
Shaikh Zayed Medical Complex, Lahore

Sumbul Naz
Senior Registrar, Department of Surgery
Dow University of Health Sciences, Karachi

Faisal Naseer
Assisatnt Professor, Department of Surgery
Dow University of Health Sciences, Karachi

Prof. Arshad Kamal Butt
Department of Gastroenterology-Hepatology
Shaikh Zayed Medical Complex, Lahore

Corresponding Author
Senior registrar
Dow University of Health Sciences, Karachi
Email:dr.sumbal_10@hotmail.com